
Concepts on Control of the Anterior Teeth Using the Lingual Appliance

Rafi Romano

For many years, lingual orthodontics was perceived as extremely complex and problematic and therefore not widely used internationally. During the last decade, the percentage of patients treated with lingual orthodontics has increased and the technique has developed to such an extent that in some cases, it is easier, quicker, and more accurate than traditional buccal orthodontics. Currently, esthetics of the anterior teeth is a significant issue in general dentistry and the most frequently cited reason for patients seeking orthodontic treatment. This article describes numerous parameters regarding the control of the anterior teeth with lingual orthodontics relative to buccal orthodontics. (Semin Orthod 2006;12:178-185.) © 2006 Elsevier Inc. All rights reserved.

Placing the anterior teeth in their most favorable and ideal position is one of the principal goals of orthodontic treatment. Although correct occlusion is dependent on the position of both anterior and posterior teeth, dental esthetics and the smile are influenced primarily by the position of the incisor teeth. The smile has become one of the most frequently discussed topics in dentistry over the last decade.

Controlling the position of anterior teeth is difficult with lingual orthodontics (LO), the reasons for which will be discussed in this article. Problems include the following: the variability in the morphology of the palatal surface of the anterior teeth; the bite plane component of some of the frequently used lingual brackets; the small interbracket distance influencing archwire rigidity and friction; the reduced distance between the point of force application to the center of resistance of the tooth; and, last, the risk of bond failures of the upper incisors brackets, all

of which contribute to specific technical difficulties.

LO has an advantage related to the anterior teeth in that there is no damage to the labial enamel surfaces and tooth movements and positions are more easily visualized during the entire treatment. Lip position is more natural and relaxed and tongue thrust habits are more easily managed.

Diagnosis, treatment planning, and treatment goals in LO should not be any different from conventional orthodontics or any other orthodontic technique.

This article will attempt to provide the orthodontist with information to achieve maximum control on the anterior teeth.

Center of Resistance (Cr)

Knowledge of the biomechanical principles of tooth movement is essential for the orthodontist to execute an individualized treatment plan. If the location of the center of resistance of a tooth or group of teeth is known, the correct moment-to-force ratio can be applied at the brackets to obtain specific centers of rotation—in other words, controlled movement.¹ Many analytical and experimental studies have been performed to determine the location of the Cr. According to most of these studies, the Cr in a single root tooth is located at 24% to 55% of the root length

Secretary Treasurer, International Federation of Esthetic Dentistry, and Invited Professor, UNIP, Sao Paulo, Brazil.

Address correspondence to Rafi Romano, DMD, MSc, 34 Habarzel St, Tel Aviv 69710, Israel. Phone: +972-3-6477878; Fax: +972-3-6477646; E-mail: rafidrromano.com

© 2006 Elsevier Inc. All rights reserved.

1073-8746/06/1203-0\$30.00/0

doi:10.1053/j.sodo.2006.05.005

measured from the alveolar crest.² While the location of the Cr of a tooth is not related to the technique, the relationship between the Cr location and the bracket placement (buccal or lingual) directly influences the magnitude and the direction of the moments created by the applied forces. The distance in the sagittal plane between a lingual bracket and the Cr is much shorter than between a buccal bracket and the Cr (Fig 1A). Therefore, pure intrusion movement in LO will be closer to bodily movement

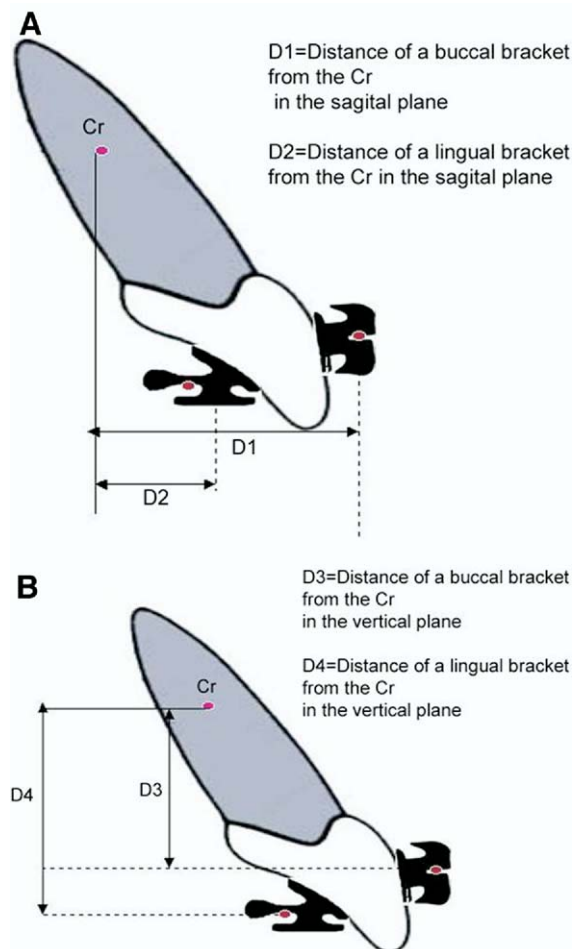


Figure 1. (A) Comparison between buccal and lingual brackets in the sagittal plane. The distance of a lingual bracket from the center of resistance (Cr) of the anterior tooth is shorter than the distance of buccal bracket from the Cr. (B) Comparison between buccal and lingual brackets in the vertical plane. The distance of a lingual bracket from the center of resistance (Cr) of the anterior tooth is longer than the distance of buccal bracket from the Cr. (Color version of figure is available online.)

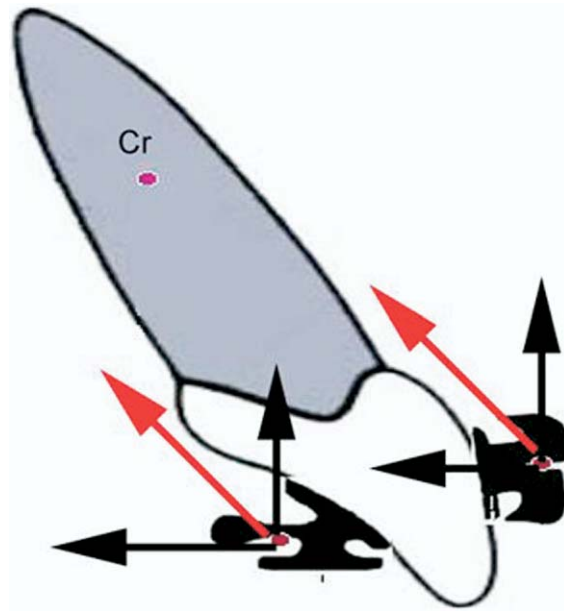


Figure 2. Comparison between the net force (resultant of vertical and sagittal forces) of buccal and lingual brackets. The resultant force applied to the lingual bracket passes behind the Cr while the force applied to a buccal bracket passes ahead of Cr. (Color version of figure is available online.)

than in buccal orthodontics (BO). The distance in the vertical plane between a lingual bracket and the Cr is greater than between a buccal bracket and the Cr (Fig 1B). Therefore, retraction movement in LO will result in a greater moment of force than in BO for the same applied load, which makes it more difficult to preserve or correct incisor torque during retraction. Since most of the clinical orthodontic movements are not pure vertical or pure sagittal in direction, it is necessary to be cognizant of the resultant force generated by the vertical and the sagittal forces. In BO, the net force will generally be ahead of the Cr, whereas in LO, it will be behind the Cr (Fig 2). The clinical implication of this geometry is that the tendency for retroclination of anterior teeth is more pronounced in LO, and therefore in certain cases it is necessary to counteract this tendency by creating a negative buccal force by incorporating a degree of labial crown torque (palatal root torque).

Moment of Force

The biomechanics of tooth movement is based on the moment of force (MOF) applied on the

bracket. Moment of force = Force \times Distance. As discussed, the Cr-bracket relationship is different in LO and this influences the MOF. The reduced interbracket distance in the incisor area in LO (around 40% of BO)³ also influences the MOF, and therefore it is more difficult to rotate, upright, or to level the anterior teeth (Fig 3). A smaller interbracket distance in LO, especially in the anterior region, makes the use of compensatory bends very difficult; however, since indirect bonding is more accurate and widely used in LO, less wire bending is required.

Wires (Size, Modulus of Elasticity, Friction)

Filling the bracket slot by incrementally increasing the wire cross section has been the basic mechanotherapeutic sequence for many fixed appliance protocols.⁴ However, under clinical conditions, the cross section of the final archwire almost never reaches the actual size of the slot because of the associated patient discomfort and the difficulty in inserting large rectangular wires into the bracket slot. Inevitably, the prescription torque, built into the bracket designed to bring the teeth to their optimal position, is not fully expressed due to a degree of “play” between the wire and the bracket slot.⁵ The most commonly used wire for space closure in LO is a 0.016×0.022 -inch stainless steel wire in a 0.018 -

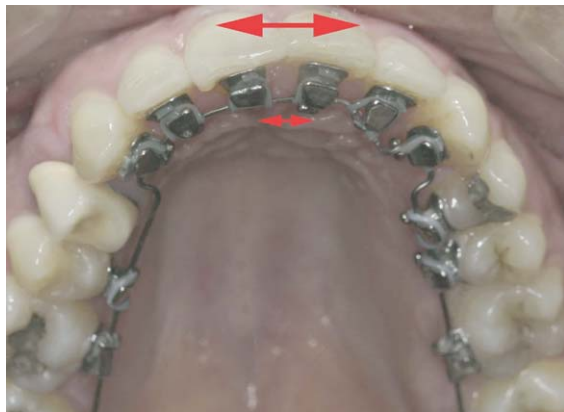

Figure 3. A lingual appliance has been bonded with Ormco-Kurz 7th generation brackets. Note the reduced interbracket distance between the upper central incisors (approximately 40%) compared with the buccal interbracket distance. Rotation correction is difficult since the lever arm is short. (Color version of figure is available online.)

inch slot and this results in approximately 14° of torque loss. The most commonly used wire for torque control in LO is an 0.017×0.025 -inch TMA wire in the 0.018 -inch slot and this results in approximately 6° of torque loss.⁶

The clinical implications of the above parameters are as follows:

- Retraction of anterior teeth using the lingual technique should not be performed with round wires even if the teeth are proclined at the start of the treatment.
- The bracket prescription should incorporate additional torque of at least 6° .
- Active torque bent into the archwire automatically induces an opposite and usually undesirable torque reaction in adjacent teeth.⁷ With the lingual technique, due to the reduced interbracket distance, this type of activation needs to be applied repeatedly in small increments, and the use of light flexible archwires is recommended.
- The key to success in LO is to allow the wire to express itself over a sufficiently long period of time. The clinician is advised to monitor the patient every 6 to 8 weeks, to check activation, engagement of the archwire, and to verify that no unexpected side effects are developing.

A clinical example of a Class I malocclusion with moderate crowding is presented in Figure 4A–C. The initial wire was 0.017×0.017 -inch Copper NiTi wire (Ormco, Glendora, CA), and after 6 months of treatment and minimal interproximal stripping, the arch is quite well aligned. Yet, on careful clinical examination (Fig 4C) it is apparent that although the wire is ligated with double overtie elastics, the freedom between the wire and the 0.018 -inch slot of the Kurz 7th generation brackets (Ormco) is still excessive and the torque is not equally expressed in all anterior teeth. The completion of alignment and torque can be achieved by changing to a 0.017×0.025 -inch archwire, or by changing the wire to beta titanium alloy (TMA). The TMA wire exhibits better load deflection characteristics with less stiffness than the stainless steel or nickel titanium wires. The surface of TMA is rougher and exhibits very high values for friction at the archwire-bracket interface.⁸ Tying the arch in with steel ligatures is preferable to ensure maximum engagement of the wire.

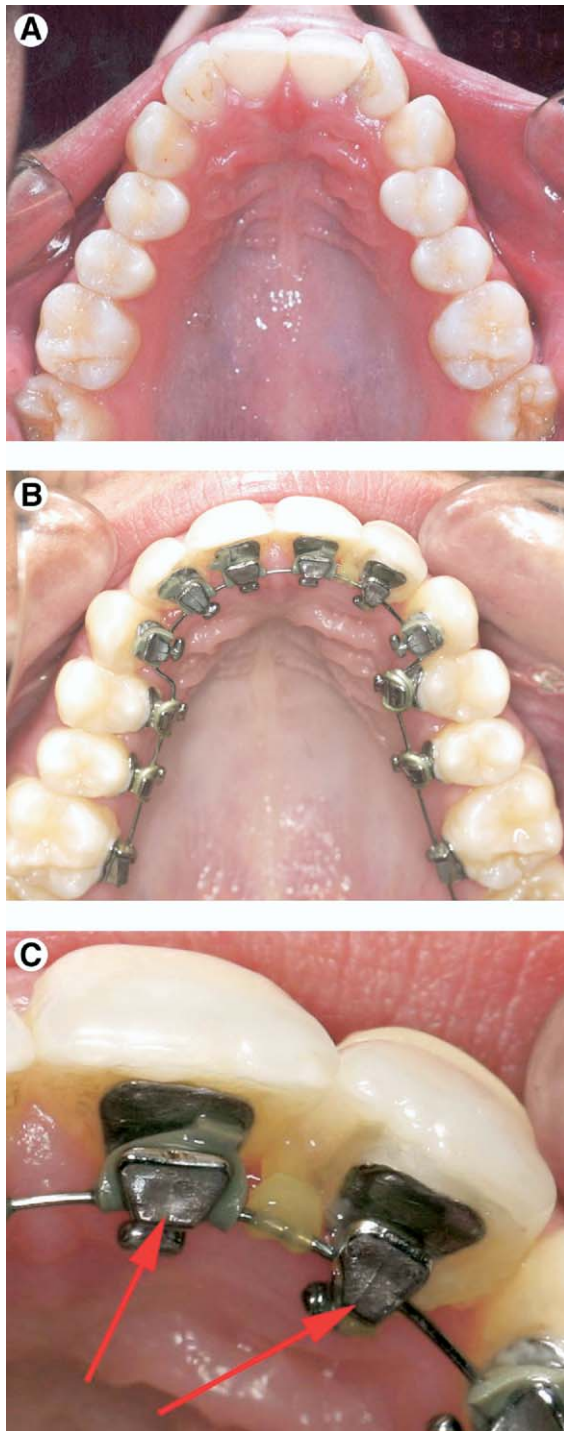


Figure 4. (A) Clinical case: Class I malocclusion with anterior crowding and narrow maxilla. Note that the lateral incisors are severely rotated and it is almost impossible to accurately bond brackets at the start of treatment. (B) The initial wire was 0.017 × 0.017-inch Copper NiTi wire. After 6 months of treatment and minimal interproximal stripping, the arch is well aligned. (C) Close examination of the picture shows that although the wire is ligated with double overtie elastics, the slack of the archwire in an 0.018-inch bracket slot is excessive and the torque is not equal on all anterior teeth. Note that the bracket bite plane on the lateral incisor is not parallel to that of the adjacent tooth. Also note that the double overtie in the anterior incisor is not sufficient to fully engage the wire into the slot; steel ligature should be used. (Color version of figure is available online.)

niques are available for indirect bonding, but the most reliable one is still a cast model set-up where the clinician can visualize and plan the final position of each tooth. The clinical example presented in Figure 5A–C, shows a case of an impacted canine tooth moved into the arch with the lingual technique. The position of the canine bracket could not be accurately determined at the start of treatment and some brackets were not ideally placed. Once traction on the canine was completed, a second impression was taken, a new set-up created, and the anterior teeth were rebonded (Archform Laboratory, Melbourne, Australia). No further wire bending was required and in less than 3 months the teeth were aligned in the desired and planned location.

Anchorage

For many years LO was considered as having poor anchorage control of the anterior teeth. This concern was mainly due to the fact that the bite plane incorporated into the Ormco-Kurz 7th generation bracket causes disarticulation in the posterior region and the concomitant tendency for retroclination of anterior teeth as previously described. Recent research indicates that the anchorage experienced with LO is greater than that experienced in equivalent clinical situations with BO, and even in cases requiring the extraction of second premolar teeth, there is minimal anchorage loss.⁹ The protocol for LO treatment is precise and most clinicians who employ LO will not start to close spaces before dental alignment is completed or before a rect-

Indirect Bonding

Orthodontists familiar with the lingual technique are well aware of the advantages and importance of indirect bonding. Numerous tech-

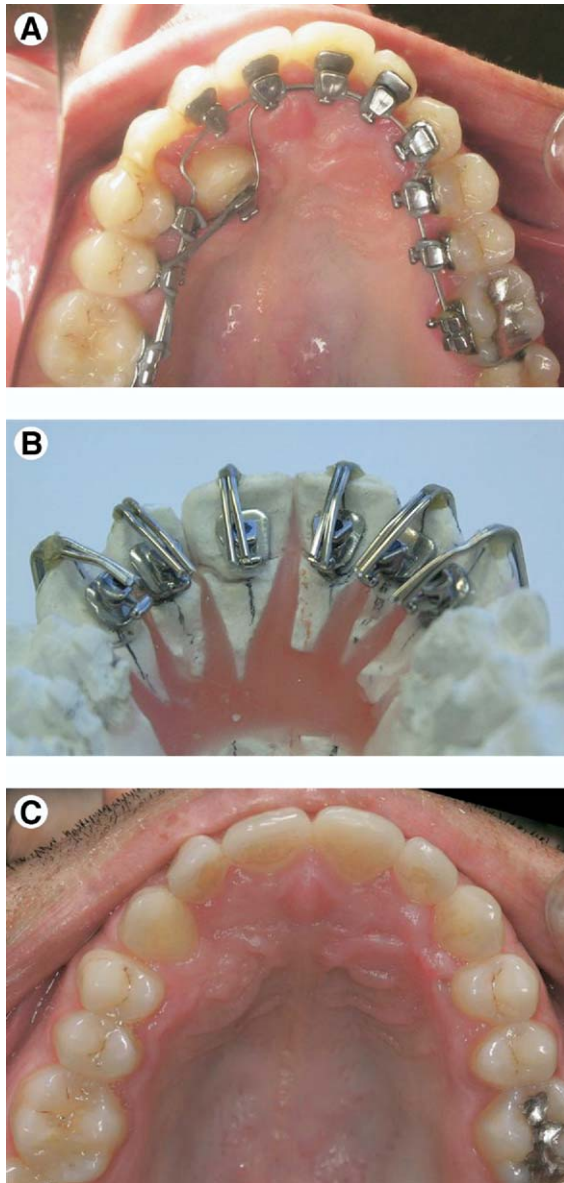


Figure 5. (A) Clinical case: Class I malocclusion with impacted canine. Accessory wire is used to move the canine into the arch. Note that the canine bracket has been bonded directly and the left lateral incisor bracket was bonded too far distally due to crowding at the start of treatment. (B) The anterior brackets were debonded and a new impression sent to the laboratory. A set-up of the teeth was performed and individual jigs were used to rebond the brackets. (C) Occlusal view of the maxillary arch on the day of debonding. (Color version of figure is available online.)

angular stainless steel archwire is well secured in the brackets.

Type of Malocclusion

There are certain types of malocclusion that are easier to treat with LO than with BO. Bite opening and anterior intrusion are easily achieved with the built-in lingual bite plane. In cases where bite closure and anterior extrusion are needed (open bite cases), the LO practitioner must employ certain biomechanical principles to overcome the natural tendency of the LO appliance to intrude the anterior teeth and to open the bite. Using the basic rules presented by Mulligan,¹⁰ by adding torque to the anterior teeth and tip-back to the molars, it is possible to create an anterior extrusion moment with concomitant posterior intrusion, and consequently the occlusal plane will be rotated in a clockwise direction and the bite will be closed (Fig 6).

The latter method was used to treat the patient shown in Figure 7A–C, where the maxillary anterior teeth were extruded and the molar teeth intruded to close the anterior open bite.

Friction

Frictional resistance is a critical factor in fixed appliance therapy. Frictional force tends to increase rapidly once the critical contact angle is exceeded.¹¹ Ideally, tipping will only occur until

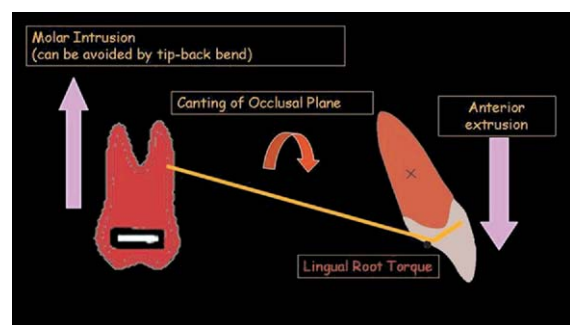


Figure 6. Sequence of action and reaction to close an open bite with LO. Lingual root torque is applied to the anterior centrals. This causes the “long arm” (from central to molar) to elevate, and therefore an intrusion force is applied on the molars and consequently an extrusion force on the centrals. The occlusal plane is tilted clockwise, helping to reduce the anterior open bite. (Color version of figure is available online.)

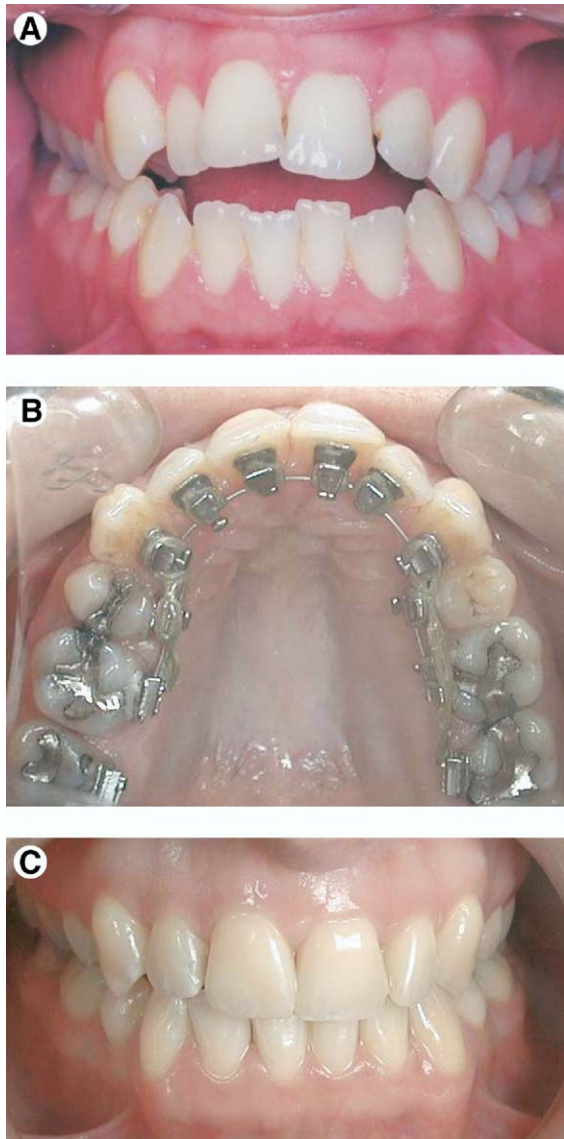


Figure 7. (A) Clinical case: Class II malocclusion with severe open bite and constricted upper arch. Treatment plan included extraction of lower second premolars and first upper premolars. (B) Case during space closure. The mechanics described in Fig 6 were used in this case. (C) Case 2 years at retention. Note the dramatic improvement in the broadness of the smile (although it is an extraction case) and the full closure of the bite. (Color version of figure is available online.)

contact is established between the diagonal corners of the bracket slot and the archwire. The amount of tipping and rotation depends on the difference between the sizes of the archwire and bracket slot. If the archwire does not bend (elas-

tically deform), the bracket angulation cannot increase beyond the critical contact angle (established angulation). Whenever a resistance to sliding occurs, some portion of the retraction force is lost.¹² In LO the archwires are usually smaller in diameter than those used in BO. Due to the small interbracket distance in LO, it is almost impossible to insert a stainless steel archwire of dimensions greater than 0.016×0.022 inches into an 0.018-inch bracket slot, or a TMA archwire of greater dimension than 0.017×0.025 inches. The use of smaller dimension archwires generates less friction in LO and consequently less torque control, yet the engagement of the wire in the presence of a small interbracket distance (especially in the anterior area) creates an angle that can be greater than the critical contact angle, resulting in resistance to sliding and some portion of the retraction force being lost.¹³ Ligation of the archwire has a critical influence on the friction values. Double overtie is the most common form of ligation with the Ormco-Kurz 7th generation brackets (Fig 8). This type of ligation generates high friction, especially in LO where the saliva is in direct contact with the brackets and the elastics.¹⁴

Periodontal Cases

Certain adult patients presenting for orthodontic treatment have existing mild to moderate periodontal disease. These patients may be at

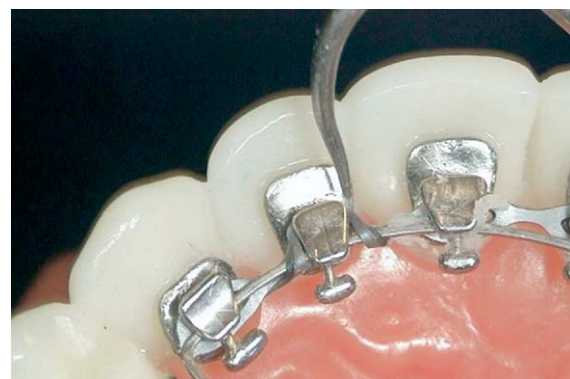

Figure 8. A view of the ligation type mostly used with Ormco-Kurz 7th generation brackets for anterior space closure. This technique combines a power chain with double overtie on each anterior tooth. The elastics generate friction, which interferes with the space closure. (Color version of figure is available online.)

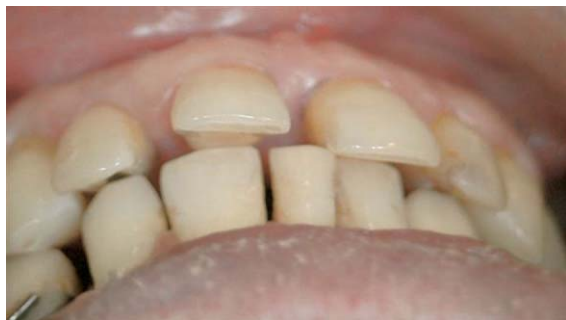

Figure 9. Patient with advanced periodontal disease. Note that tooth No. 11 moved labially due to the traumatic occlusion and inadequate posterior support. Posterior bite blocks should be added while treating such patients to avoid additional trauma to the anterior teeth. (Color version of figure is available online.)

risk for developing further periodontal breakdown during orthodontic therapy.¹⁵ Diedrich¹⁶ has found that occlusal forces contribute to the direction and progression of tooth migration. Lack of posterior occlusal contacts as a result of tooth extraction or molar tipping (or due to the anterior bite plane incorporated in the LO bracket) may lead to eccentric sliding of the lower jaw. On the assumption that the periodontal disease is controlled and monitored by a periodontist, successful orthodontic treatment of these patients by using the lingual appliance requires specific considerations and a biomechanical approach.¹⁷ The force levels used to retract anterior teeth in patients with advanced periodontitis should be considerably lighter than in patients without periodontal disease. Anterior occlusal contacts should be avoided by placing temporary composite posterior bite planes on the molar teeth until the interincisal angle has been corrected (Fig 9).

The Art of the Smile

Many patients and clinicians are currently seeking guidelines as to what the perfect smile should look like, how it should be designed, and whether we should attempt to standardize the individual smile.¹⁸

Striving to create the ideal smile is common to both LO and BO practitioners. LO, however, is much more demanding since the labial surface of the enamel remains untouched and the soft tissues are in their relaxed position. While

this may be considered an esthetic advantage during treatment, it can also be a disadvantage, particularly when undesired side effects of the orthodontic treatment occur. Establishing the correct torque can take several months, and if a rectangular wire cannot be fully engaged because of crowding, it can take even longer. In-

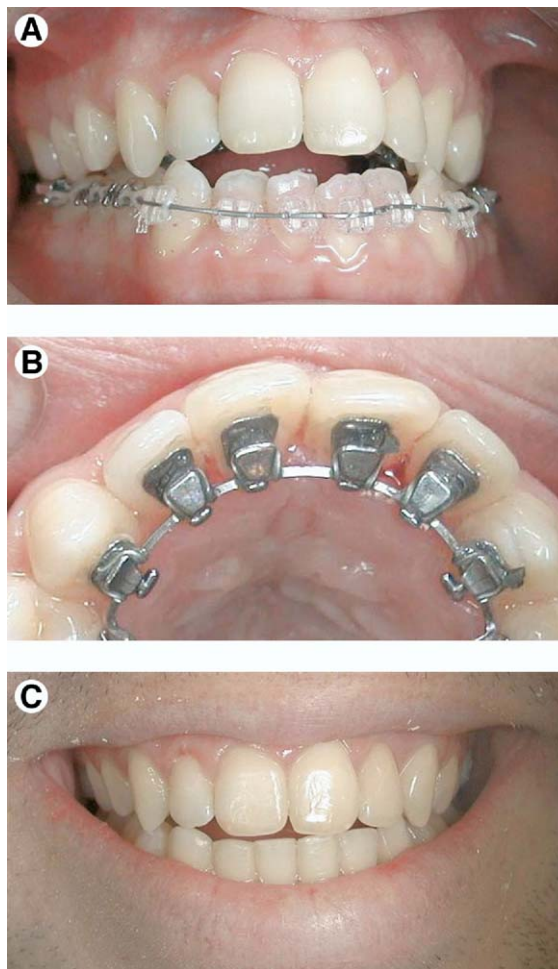


Figure 10. (A) Clinical case: Class III malocclusion, open bite, and crowding. Note the uneven height of the anterior central incisors. (B) Occlusal view of the maxilla. Note that the bracket bite planes are not parallel to each other and to the occlusal plane, indicating that the torque has not been fully expressed yet, and most probably, this is the reason for the temporary unaesthetic appearance. (C) Same patient 6 months after debonding: 3 months with Copper NiTi 0.017 × 0.017-inch and 3 months with TMA 0.017 × 0.025-inch wire fully expressed the prescription torque. Note the bite closure and the improvement in the incisal and gingival lines and in the broadness of the smile. (Color version of figure is available online.)

correct torque can affect the vertical position of the anterior teeth. An anterior tooth with a different torque angle from the adjacent teeth will be shorter or longer (depending on the torque values) (Fig 10A–C). Since the anterior teeth are more visible at all times when employing LO, patients are more aware of tooth positions and therefore special care should be taken in cases where esthetics may be compromised during treatment.

Conclusion

Knowledge of the biomechanics of LO, particularly where it differs from BO, is essential. Treatment with LO can be as successful and as satisfying as BO. Esthetics is a most significant issue in orthodontics, particularly for adult patients, and it is incumbent on clinicians to be aware of the necessity to fulfill the patients' concerns and expectations not only relative to the final result, but also in their desire to receive the most esthetically available appliance.¹⁹

References

1. Yoshida N, Jost-Brinkmann PG, Koga Y, Mimaki N, Kobayashi K: Experimental evaluation of initial tooth displacement, center of resistance, and center of rotation under the influence of an orthodontic force. *Am J Orthod Dentofacial Orthop* 120:190-197, 2001
2. Goren S, Zoizner R, Geron S, Romano R: Lingual orthodontics (LO) versus buccal orthodontics (BO): biomechanical and clinical aspects. *J Lingual Orthod* 3:1-7, 2002
3. Geron S, Romano R, Brosh T: Vertical forces in labial and lingual orthodontics applied on maxillary incisors—a theoretical approach. *Angle Orthod* 7:195-201, 2004
4. Gioka C, Eliades T: Materials-induced variation in the torque expression of preadjusted appliances. *Am J Orthod Dentofacial Orthop* 25:323-328, 2004
5. Meling TR, Odegaard J: The effect of cross-sectional dimensional variations of square and rectangular chrome-cobalt archwires on torsion. *Angle Orthod* 68:239-248, 1998
6. Sebanic J, Brantley WA, Pincsak JJ, Conover JP: Variability of effective root torque as a function of edge bevel on orthodontic arch wires. *Am J Orthod* 86:43-51, 1984
7. Parkhouse RC: Rectangular wire and third-order torque: a new perspective. *Am J Orthod Dentofacial Orthop* 113:421-430, 1998
8. Krishnan V, Kumar KJ: Mechanical properties and surface characteristics of three archwire alloys. *Angle Orthod* 74:825-831, 2004
9. Geron S, Shpack N, Kandos S, Davidovitch M, Vardimon AD: Anchorage loss—a multifactorial response. *Angle Orthod* 73:730-737, 2003
10. Mulligan TF: Common sense mechanics. *J Clin Orthod* 14:180-189, 1980
11. Thorstenson GA, Kusy RP: Resistance to sliding of self-ligating brackets versus conventional stainless steel twin brackets with second-order angulation in the dry and wet (saliva) states. *Am J Orthod Dentofacial Orthop* 120:361-370, 2001
12. Park JH, Lee YK, Lim BS, Kim CW: Frictional forces between lingual brackets and archwires measured by a friction tester. *Angle Orthod* 74:816-824, 2004
13. Khambay B, Millett D, McHugh S: Archwire seating forces produced by different ligation methods and their effect on frictional resistance. *Eur J Orthod* 27:302-308, 2005
14. Kusy RP, Whitley JQ: Resistance to sliding of orthodontic appliances in the dry and wet states: influence of archwire alloy, interbracket distance, and bracket engagement. *J Biomed Mater Res* 52:797-811, 2000
15. Mathews DP, Kokich VG: Managing treatment for the orthodontic patient with periodontal problems. *Semin Orthod* 3:21-38, 1997
16. Diedrich PR: Orthodontic procedures improving periodontal prognosis. *Dent Clin North Am* 40:875-887, 1996
17. Geron S: Managing the orthodontic treatment of patients with advanced periodontal disease: the lingual appliance. *World J Orthod* 5:324-331, 2004
18. Romano R: *The Art of the Smile: Integrating Prosthodontics, Orthodontics, Periodontics, Dental Technology, and Plastic Surgery in Esthetic Dental Treatment*. Berlin, Germany, Quintessence, 2005
19. Stamm T, Weichman D: Relation between second and third order problems in lingual orthodontic treatment. *J Lingual Orthod* 1:5-11, 2001