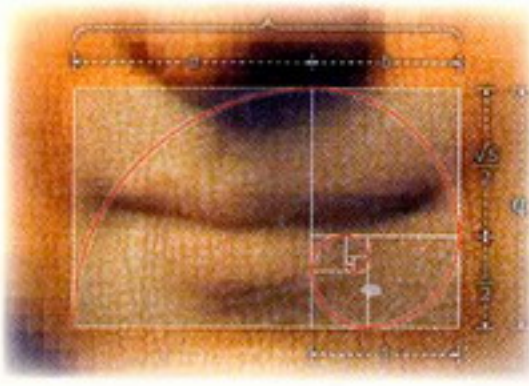

# Simple Techniques for Optimal Smile Modification

RAFI ROMANO, DMD, MSC

**ABSTRACT** Orthodontics is no longer a treatment modality for moderate or severe malocclusion. Patients of all age groups seek help in tooth repositioning. Esthetic demands are extremely high and clinicians need to be more creative and more open to alternative techniques that will suit the demand for invisible treatment, at reasonable costs, maximum accuracy, and with relative comfort. A few simple techniques are described for very common orthodontic problems.

## AUTHOR

Rafi Romano, DMD, MSC, is an orthodontist in private practice in Tel Aviv.

Although the smile has been the focus of all dental practitioners for many years, it has been investigated and discussed more extensively in the last decade. Techniques such as power bleaching and porcelain and composite veneers are part of almost every esthetic treatment.<sup>1,2</sup>

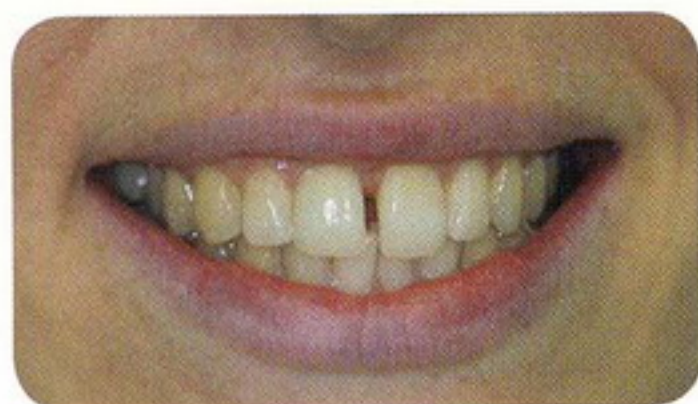Orthodontics has focused on its foundations in measuring the entire craniofacial complex trying to achieve the optimal jaws and teeth position regardless of the outcome in terms of esthetic proportions.<sup>3</sup>

A smile is defined and described differently by orthodontists.<sup>4-6</sup> These definitions were modified by prosthodontists and periodontists who realized that the smile can easily be altered and improved by simple procedures that will supplement the orthodontic movements, and plastic surgeons added more pa-

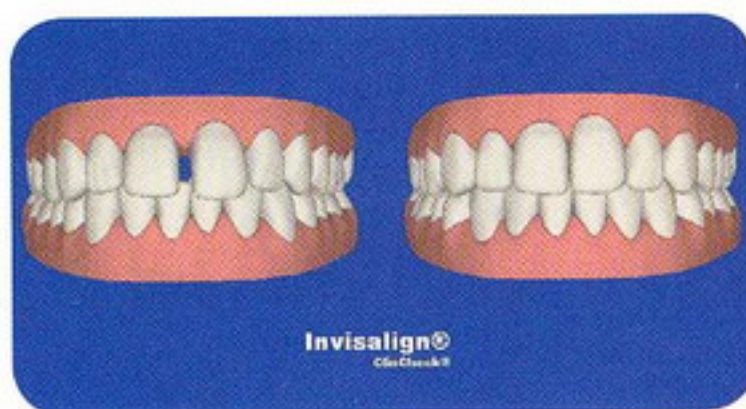rameters related to aging, gravity effects on the face and lip muscles, continuous growth of the nose, and the diminished soft tissue and bony volumes.<sup>7-9</sup>

Fashion and beauty magazines and commercials frequently ignore the parameters that dental clinicians considered of the highest importance, as long as harmony is preserved. Yet, looking closely at most fashion models, many imperfections are observed such as misaligned teeth, enlarged overjet, uneven incisal edges, and midline deviations. A clinical study that compares the perception of dentists and lay people to altered dental esthetics demonstrated there is a tendency to ignore minor imperfection as long as it does not jeopardize the harmony of the smile.<sup>10</sup>

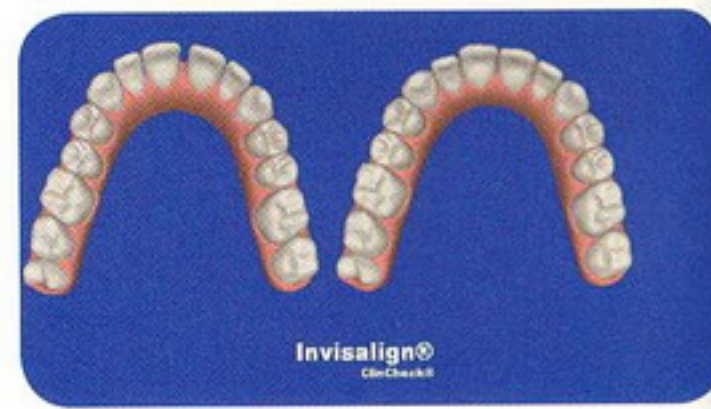
This article will present dental clinicians with a few simple techniques that facilitate the enhancement of the esthetics of the smile improvement.



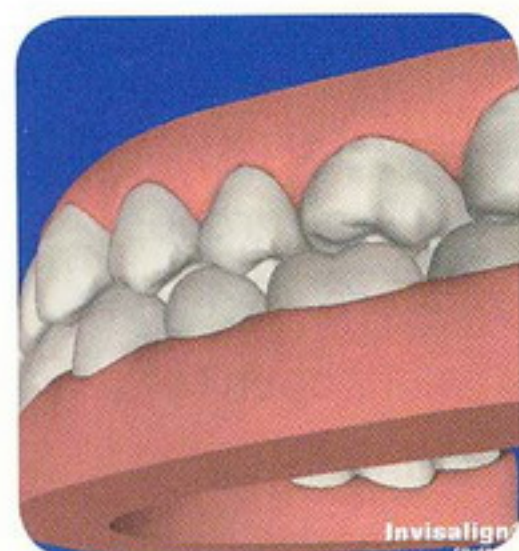
**FIGURE 1A.** Frontal view of the patient's smile. Note the black corridors due to the constricted arch and the lack of anterior papilla due to the opened diastema.



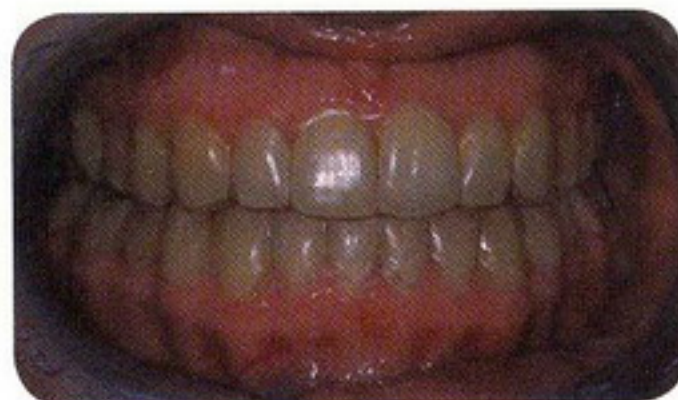**FIGURE 1B.** Frontal view.



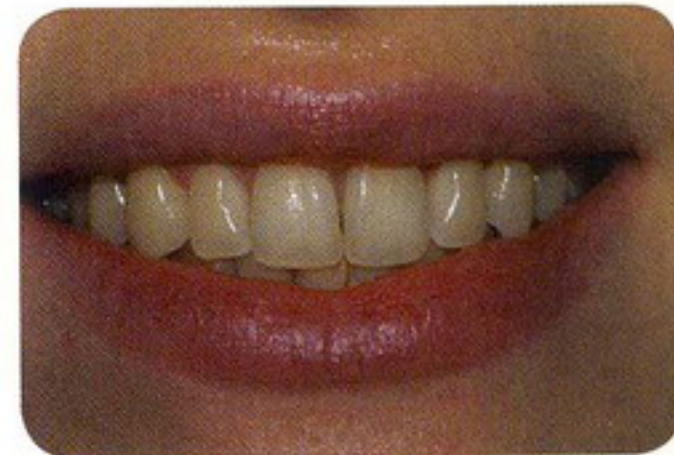
**FIGURE 1C.** Maxillary occlusal view.



**FIGURE 1D.** Lateral view, note occlusal contacts.



**FIGURE 1E.** Patient with the Invisalign on both arches. Note the esthetic appearance even from a close-up view.



**FIGURE 1F.** Frontal view of the final result. Note the harmony of the arch shape and the gingival architecture.

### Arch Expansion

Expanding the posterior segments of both upper and lower arches has tremendous effects on the smile. The black corridors created by a narrow and triangular arch can easily be modified by merely changing the torque of the posterior teeth. Andrews defined negative torque values to his straight wire brackets, which caused a very unesthetic appearance.<sup>10</sup> Expansion can be done by various techniques like rapid maxillary expansion, quad-helix, regular or self-ligating braces, and more. The Invisalign technique has been found to be the most predictable and accurate.

While closing spaces caused by spaced dentition or by extractions, the arch tends to narrow; arch coordination is not easily monitored with the edgewise technique, and the expansion tends to relapse quite fast after the debonding due to poor cooperation of the patient who is requested to wear vacuum-form retainers for nights over a long time. Patients treated with the Invisalign technique will become accustomed to the appliance during the

treatment and will better accept the same type of appliance for retention.

**FIGURES 1A-F** show the usage of the Invisalign technique to expand the maxilla and to close anterior diastema. The 3-D model enables one to forecast the shape of the maxilla and the relation to the opposing arch in a close-up view and check all, not only the esthetic parameters but also the occlusal factors (**FIGURE 1D**). Stability of arch expansion is a subject of debate between clinicians.<sup>12</sup> Yet, the current tendency of long to lifetime retention of the orthodontic end result with vacuum retainers for night-wear and/or fixed bonded retainers will definitely guarantee long-term stability.

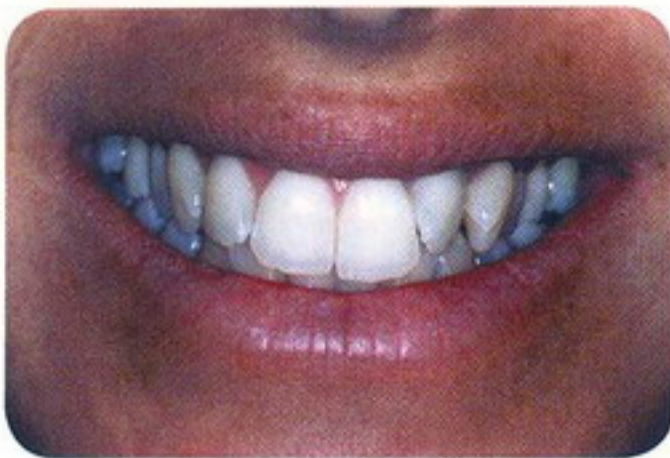Expansion also is easily performed with lingual orthodontics when the bite plane is used to eliminate any posterior interference. **FIGURES 2A-E** demonstrate the use of a lingual appliance (Ormco, Kurz Generation 7) to expand the arch and give it a rounder shape. Indirect bonding techniques enable the clinicians to plan the teeth's exact final required positions and to achieve the highest standards of smile design.

### Incisal Edges and Gingival Height Control

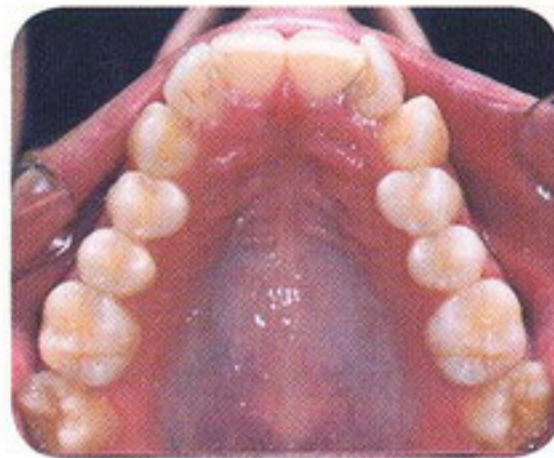
Many clinical cases face the problem of uneven incisal edges or gingival height discrepancies. A simple method to solve this problem is described in **FIGURES 3A-F**. Patient is 29 years of age, with tooth No. 11 shorter than No. 21. The gingival level is also higher. Treatment options were to shorten tooth No. 21 (**FIGURE 4D**), which was rejected by the patient and not highly recommended by the author due to the low upper lip line and the limited exposure of upper incisors during smiling. Composite restoration was not chosen since the preparation had to be extensive to provide enough retention.

The patient preferred the forced eruption option for tooth No. 11 with an esthetic invisible appliance. Invisalign and lingual orthodontics could have been a good option, yet the mechanical limitations of Invisalign (extrusion movements are the most difficult for clear aligners) and lingual orthodontics (which would have required posterior bite blocks to open the deep

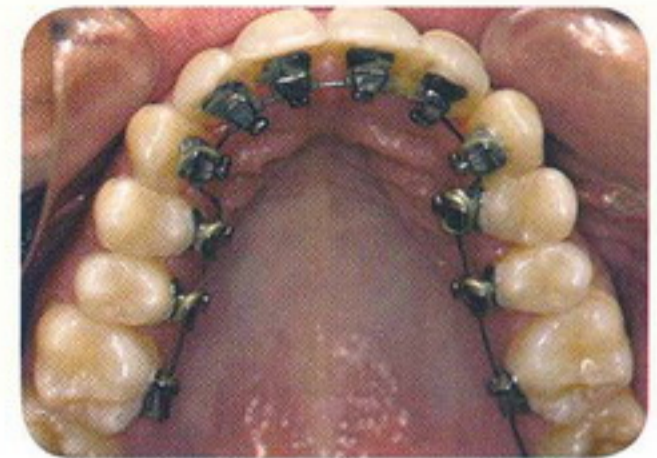CONTINUES ON 345



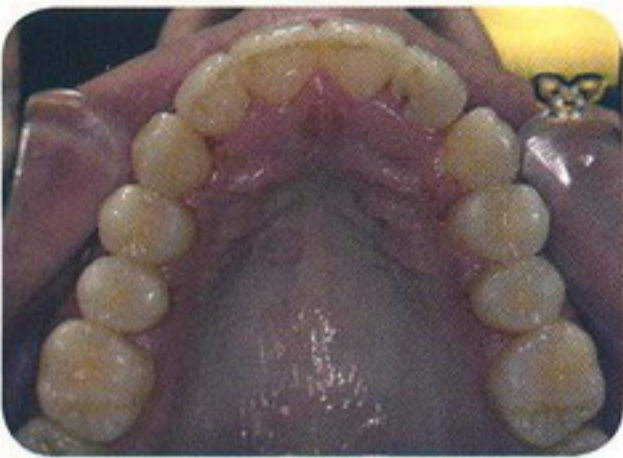
**FIGURE 2A.** Occlusal view of patient with constricted maxilla and misaligned teeth.



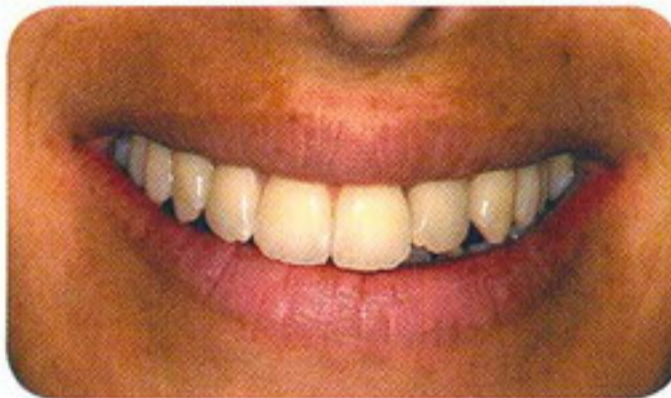
**FIGURE 2B.** Maxillary occlusal view of patient with constricted maxilla and misaligned teeth.



**FIGURE 2C.** Occlusal view of the maxilla with the lingual appliance. Note the bite plane integrated in the Ormco Kurz Generation 7 brackets that enable anterior bite opening and elimination of posterior occlusal contacts to achieve rapid and efficient expansion.



**FIGURE 2D.** Occlusal view of patient at debonding of braces.



**FIGURE 2E.** Frontal view of smile on completion of treatment.

#### ORTHODONTICS, CONTINUED FROM 346

bite and enable the extrusion movement) as well as the cost involved, left these options as a last solution. Clear braces were also not accepted by the patient due to their limited esthetics.

Coated nickel titanium wire was bonded to teeth Nos. 12 and 21 and the wire was then "pulled" upward and bonded on tooth No. 11 (**FIGURE 3D**). Three weeks later, the tooth leveled with the adjacent tooth and the gingival level has improved as well (**FIGURES 3E-F**). A fixed bonded retainer was used to retain the results at minimal cost to the patient.

#### Minimal to Mild Crowding

Class I crowding is the most common malocclusion. The treatment plan for the anterior six teeth is a target of almost any esthetic dentist who is concerned with the limited reconstruction options that one might have if he were to skip the alignment of the teeth prior to any esthetic treatment modality such as crowns, veneers or composite restorations. Treatment options in misaligned

anterior teeth can also be to cover them with veneers, but the excessive amount of tooth material needed to be removed in order to achieve a harmonious arch shape, the risk of loss of the vitality of the teeth together with the great costs involved in such treatment modality, renders this option as low in priority. **FIGURES 4A-G** show a typical case that demonstrates these conflicts. Tooth No. 21 needed an esthetic restoration. Teeth Nos. 12 and 22 were buccally inclined and teeth Nos. 11 and 21 were retroclined (**FIGURES 4A-B**). The treatment plan included buccal movement of the upper central incisors in order to place them in a broader arch, which will contribute not only to the shape of the arch but will also gain space needed to solve the mild crowding. Minimal interproximal reduction was performed to gain the remaining necessary space.

A cast model was trimmed in the mesio-buccal aspect of teeth Nos. 12 and 22 to create palatal and rotation force vector (**FIGURE 4B**) and a ball-shaped hole was trimmed on the midpalatal aspect

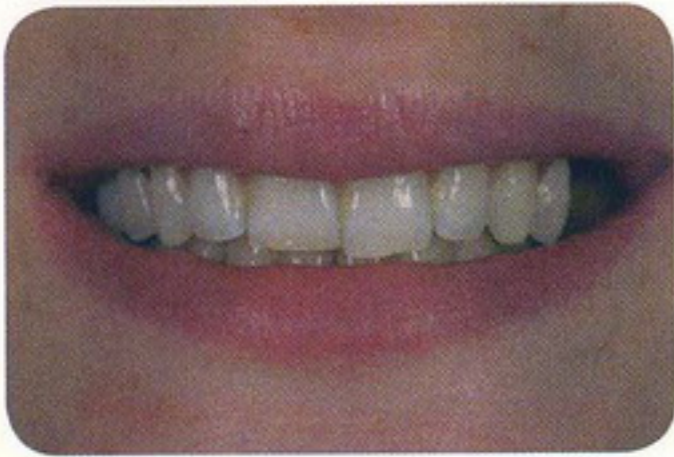of teeth Nos. 11 and 21 to create buccal force vector. Pink wax (or flowable composite) was attached to the opposite side of the planned pressure points in order to enable the teeth movement (**FIGURE 4C**). Attention should be paid not to release the part of the tooth that one does not wish to move (such as the distopalatal aspect of teeth Nos. 12 and 22).

Clear aligners (Raintree Essix), were used to correct the malocclusion (**FIGURE 4D**). The clear aligner is worn 22 hours a day for two to three weeks, and it is then replaced with an additional one, which is also made in-office with a vacuum former at minimal cost. Esthetics was preserved throughout the whole treatment. Five months after treatment was initiated with seven aligners in total (**FIGURES 4E-G**), the patient was referred to the prosthodontist to complete the esthetic restoration of tooth No. 21.

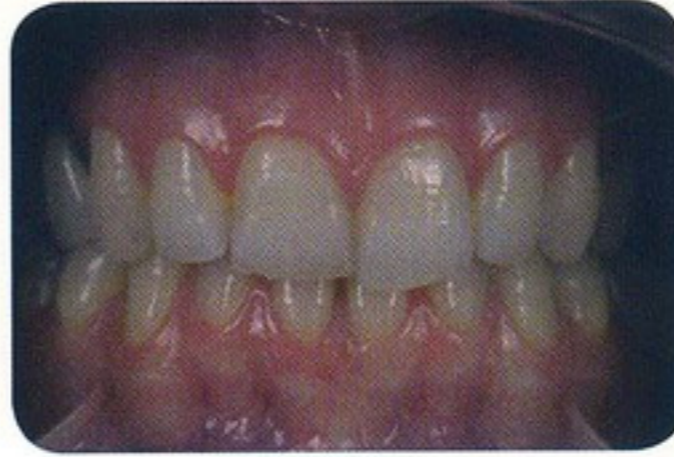#### Periodontal Cases

A smile is often affected by a poor periodontal condition, with diminished bone support that eventually contributes to the teeth buccal migration with spaces opening. Tongue thrust habits can aggravate the already buccally inclined teeth. **FIGURES 5A-H** demonstrate a case in which lower incisors migrated forward with 4 mm medial diastema. The enlarged space with poor oral hygiene caused loss of the interdental papillae. Anterior lower teeth had mobility

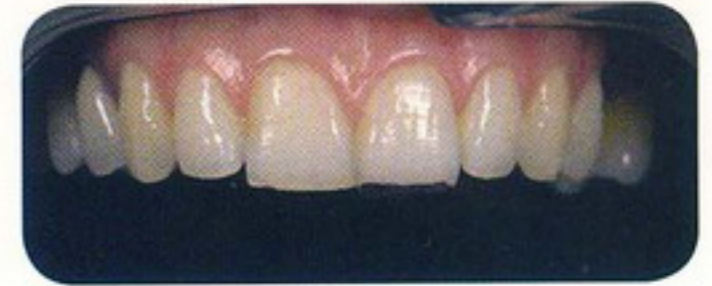CONTINUES ON 350



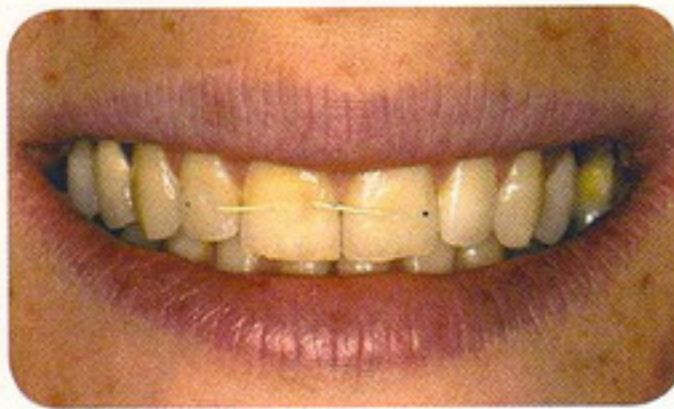**FIGURE 3A.** Frontal view of the smile showing the uneven incisal edges between teeth Nos. 11 and 21.



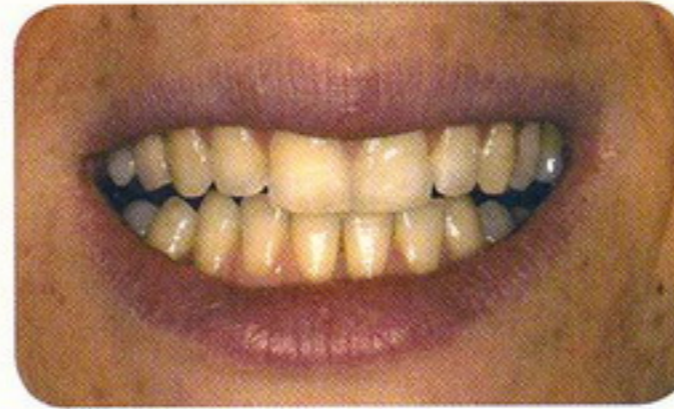**FIGURE 3B.** Maxillary occlusal view showing the uneven gingival level of teeth Nos. 11 and 21.



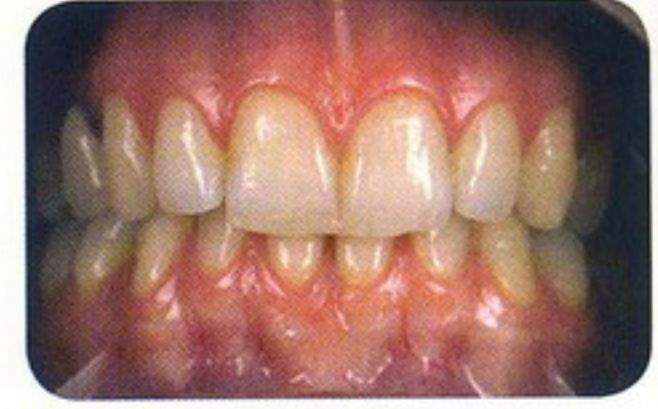**FIGURE 3C.** Figure was modified by shortening the incisal edge on tooth No. 21. Although incisal edges are leveled, gingival level is still unesthetic.



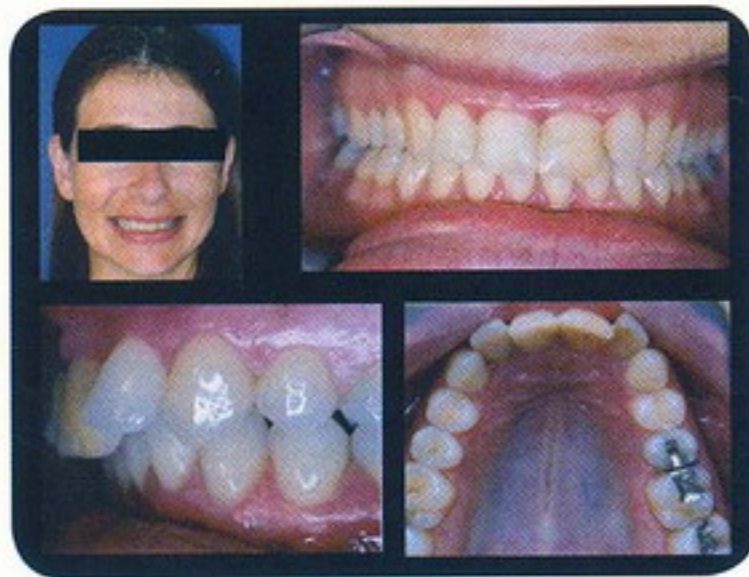
**FIGURE 3D.** Coated nickel titanium wire was bonded to teeth No. 12 and No. 21 and then the wire was "pulled" upward and bonded on tooth No. 11.



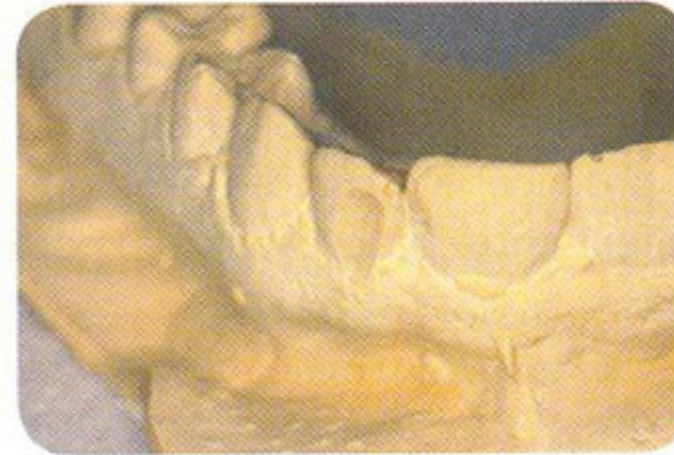**FIGURE 3E.** Frontal view of the smile at debonding showing harmonious smile.



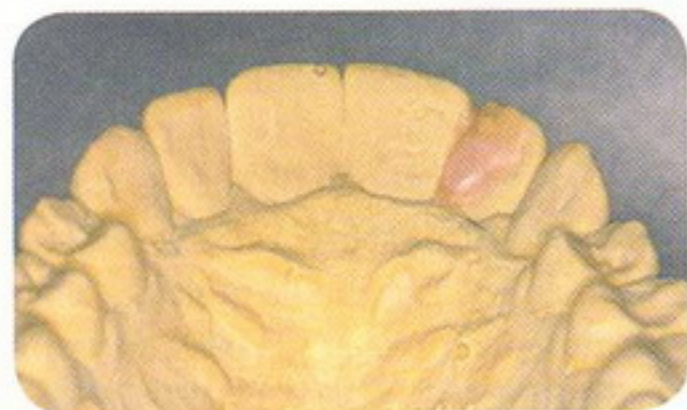
**FIGURE 3F.** Frontal view of the occlusion at debonding showing even incisal edges and acceptable gingival level.



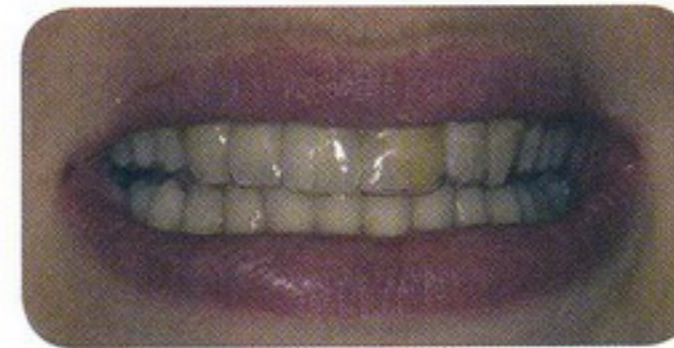**FIGURE 4A.** Various views of the patient's smile and occlusion. Note the buccal inclination of teeth Nos. 12 and 22 and the retroclination of teeth Nos. 11 and 21.



**FIGURE 4B.** Cast model was trimmed in the mesio-buccal aspect of teeth Nos. 12 and 22 to create palatal and rotation force vector and a ball-shape whole was trimmed on the midpalatal aspect of teeth Nos. 11 and 21 to create buccal force vector.



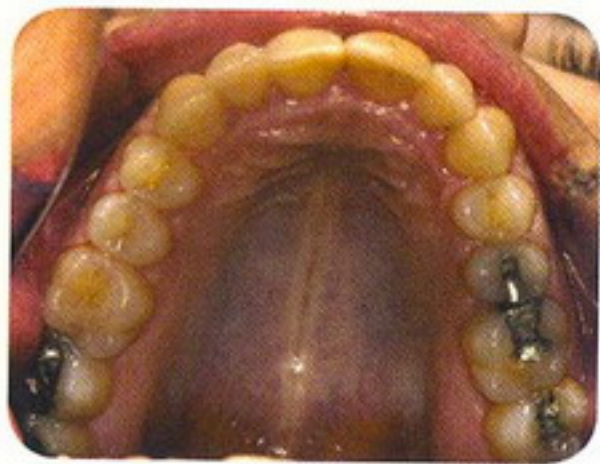
**FIGURE 4C.** Pink wax (or flowable composite) was attached to the opposite side of the planned pressure points in order to enable the teeth movement.



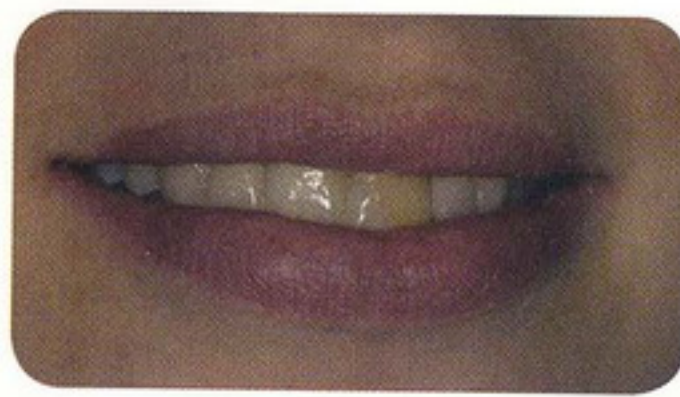
**FIGURE 4D.** Clear aligners (Raintree Essix) were used to correct the malocclusion.

**ORTHODONTICS, CONTINUED FROM 348**  
 stage II. The smile became very unattractive (**FIGURE 5A**). Radiographic records showed minimal bone support for teeth Nos. 32-42 of less than 4 mm (**FIGURES 5B-C**) and proclination of the lower incisors with protuberance and curling of the lower lip (**FIGURE 5D**). Treatment options included extraction of teeth Nos. 31 and 41 to be replaced by implant-supported restorations, fixed bridge restoration with wide, enlarged, anterior incisors, or orthodontic treatment. The patient and referring dentist were afraid the diminished bone support and the teeth mobility, together with a space of almost a tooth width, would minimize the prognosis of the orthodontic treatment and aggravate the periodontal disease. Since the literature and the author's own experience did not support this theory, it was decided to close all spaces by means of small, continuous forces and fixation of the teeth with fixed braces, which immediately prevented the trauma to the bone caused by the mobility of the teeth and the traumatic contacts with the opposite arch<sup>13</sup> (**FIGURES 5E-H**).

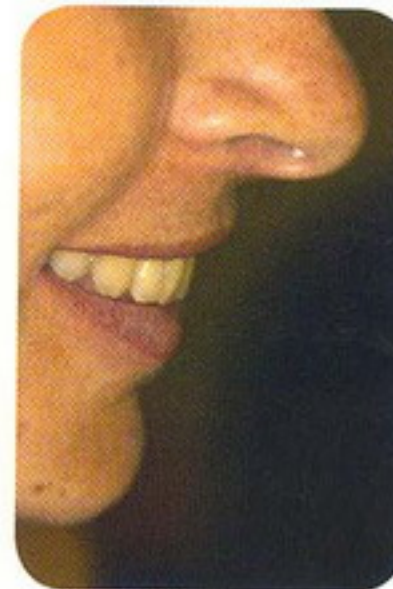Clear braces (Forestadent Brilliant series) were used to align upper and lower



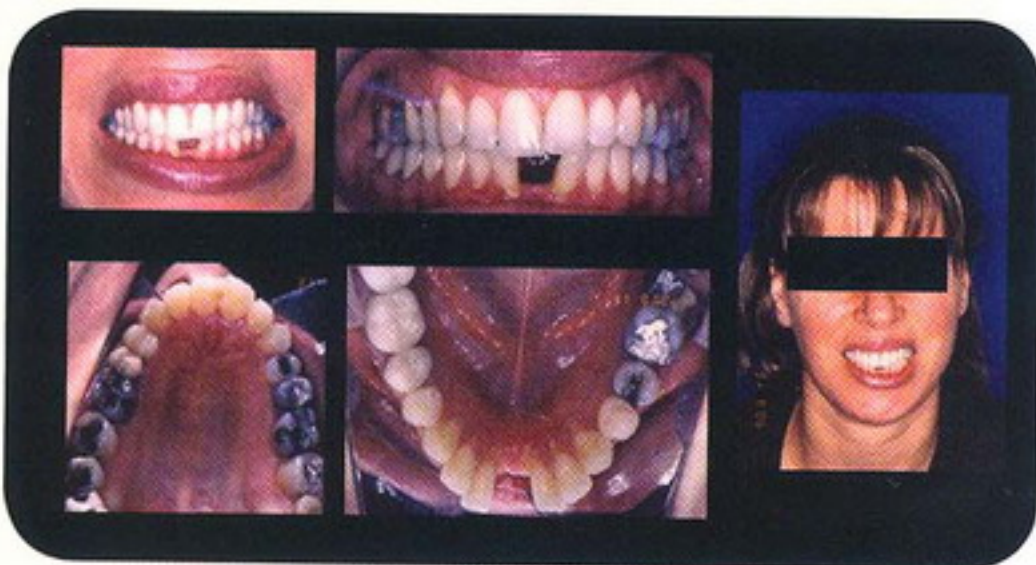
**FIGURE 4E.** Occlusal view of the maxilla at the end of treatment. Total treatment time was five months with seven sequential clear aligners.



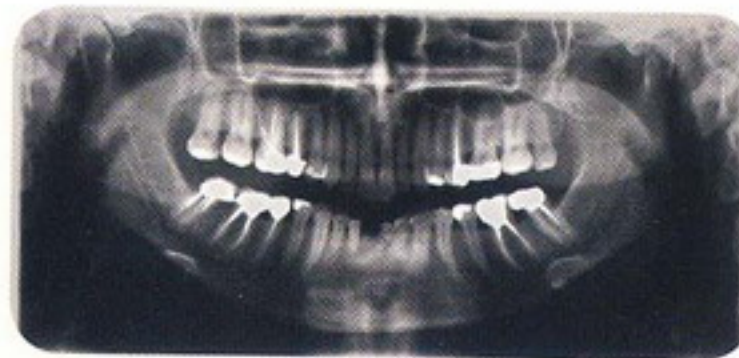
**FIGURE 4F.** Frontal view of the smile at the end of treatment before reconstruction of tooth No. 21.



**FIGURE 4G.** Profile view of the face during smile at the end of treatment. Note the esthetic emergence profile of the anterior teeth showing that no proclination was performed.



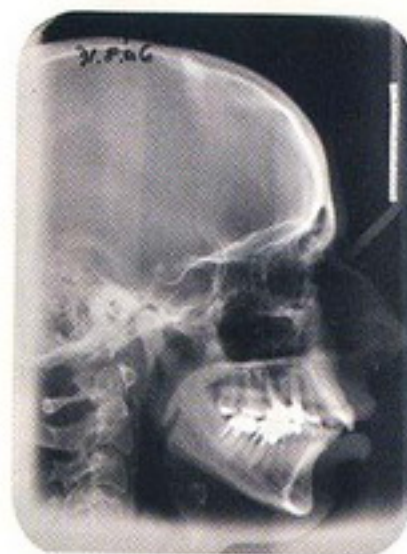**FIGURE 5A.** Various views of the patient's smile and occlusion. Note the proclination of the lower anterior teeth with very big diastema between the lower central incisors, which also created loss of the papilla and unesthetic smile.



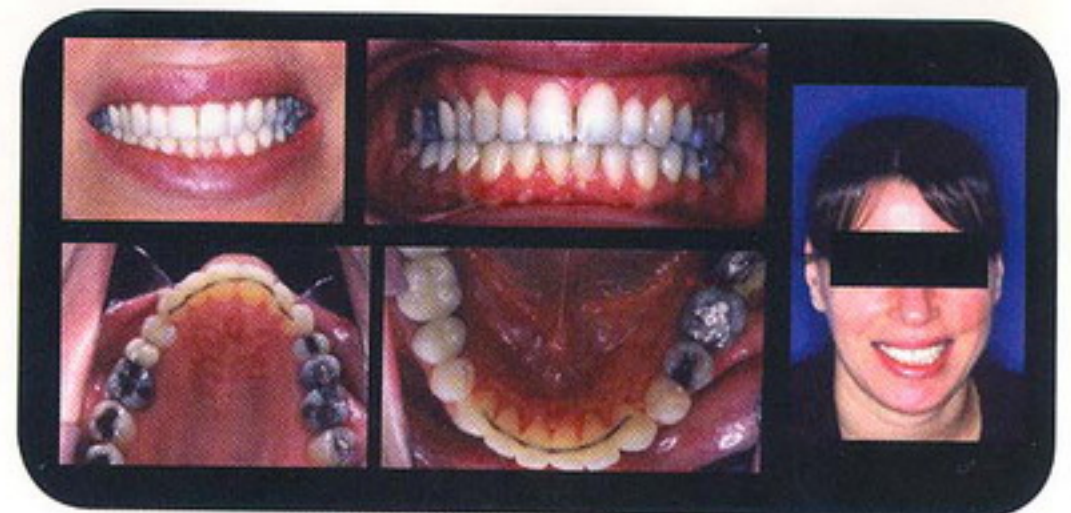
**FIGURE 5B.** Panoramic radiograph showing the minimal bone support for the anterior lower incisors. Shortening of the teeth length is due to their proclination.



**FIGURE 5C.** Periapical radiographs showing around one-third bone support for the roots of the anterior lower incisors.



**FIGURE 5D.** Cephalometric radiograph showing the proclination of the anterior lower incisors.



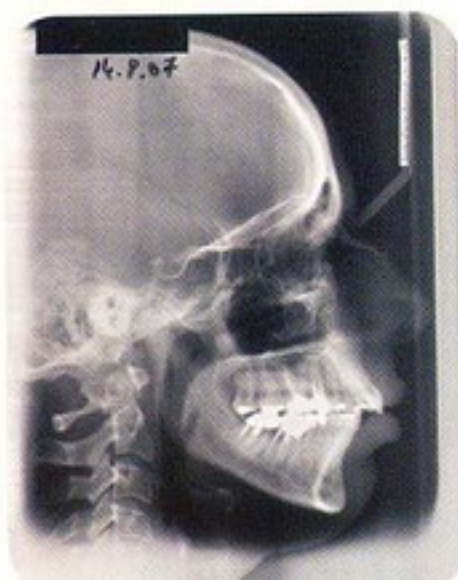**FIGURE 5E.** Various views of the patient's smile and occlusion. Note the great improvement in the overall esthetics of the smile. Fixed bonded retainers together with vacuum form for nights were used to retain the result.

teeth with minimal force application and monthly hygiene control. Twelve months later, braces were debonded and teeth were fixed with a bonded retainer (3-3) and a vacuum retainer for nights. Although the overjet was enlarged, the overall esthetics was tremendously improved, bone support was increased by more than 100 percent, and the central papilla grew to a normal shape and texture.

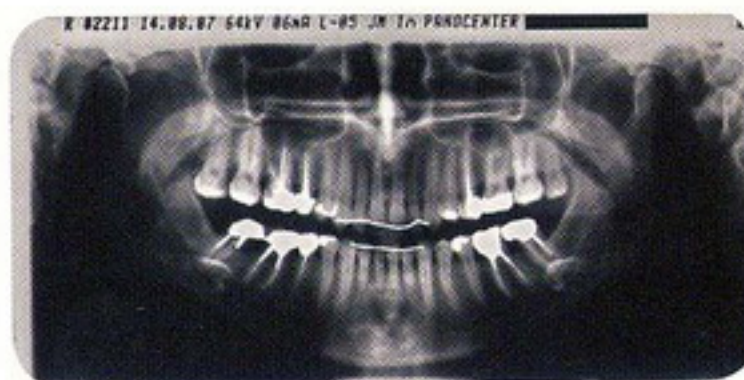
Clear aligners such as Invisalign are a good treatment choice when periodontal disease is spread to a greater extent and the anchorage value of the posterior teeth is relatively poor, as shown in **FIGURES 6A-D**. The splint of the arch with the vacuum retainer provides stability to the already mobile teeth and enables the clinician to control the level of the forces and the flow of the treatment more carefully. ■■■■

**REFERENCES**

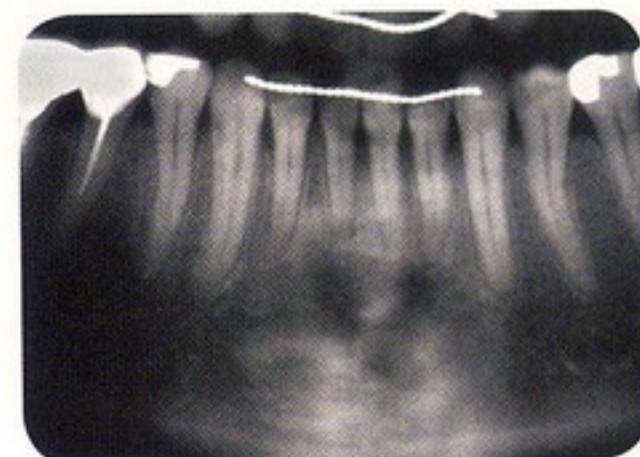1. Kihn PW, Vital tooth whitening. *Dent Clin North Am* 51(2):319-31, April 2007.
2. Strassler HE, Minimally invasive porcelain veneers: Indications for a conservative esthetic dentistry treatment modality. *Gen Dent* 55(7):686-94; quiz 695-6, 712, November 2007.
3. Sarver DM, Ackerman MB, Dynamic smile visualization and quantification and its impact on orthodontic diagnosis and treatment planning, in Romano R, *The Art of the Smile*: Quintessence publishing, (Germany) 99-139, 2005.
4. Hulseley CM, An esthetic evaluation of lip-teeth relationships present in the smile. *Am J Orthod* 57:132-4, 1970.
5. Zachrisson BU, Esthetic factors involved in anterior tooth



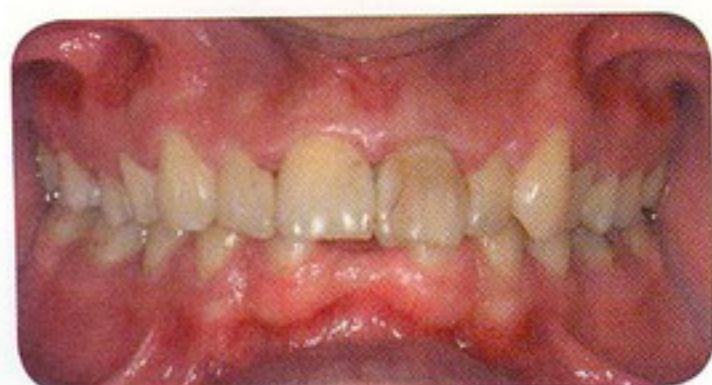**FIGURE 5F.** Cephalometric radiograph at the end of treatment showing the correction of the inclination of the proclined.



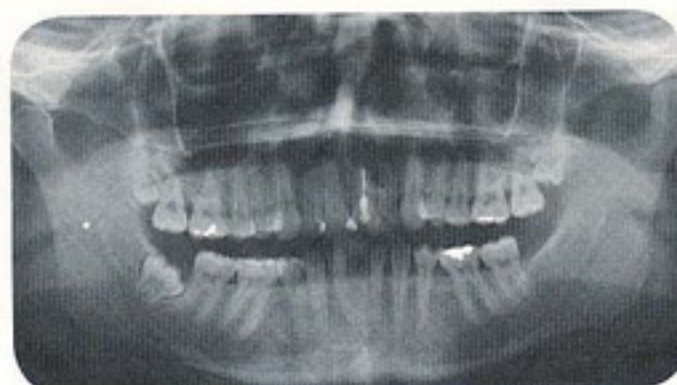**FIGURE 5G.** Panoramic radiograph at the end of treatment showing parallel inclination of the lower anterior incisors and augmentation of the bone surrounding the root surface.



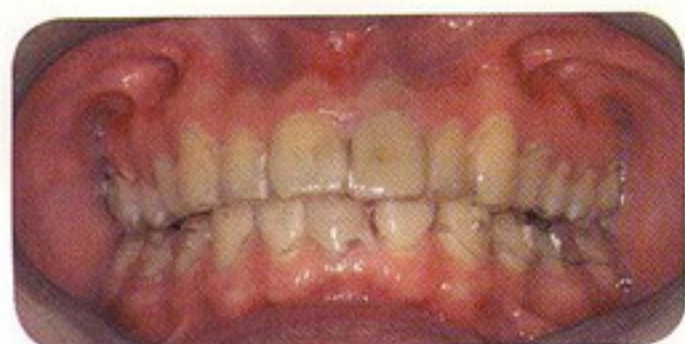**FIGURE 5H.** Periapical radiographs at the end of treatment showing the augmentation of bone in the lower anterior region and the optimal conditions for papillas reconstruction.



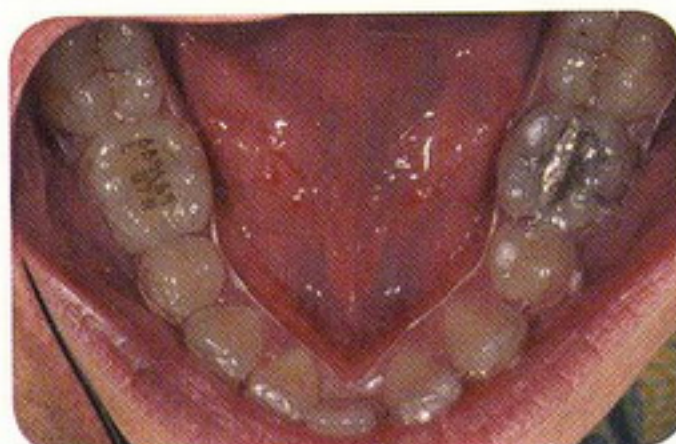**FIGURE 6A.** Frontal occlusal view showing the complex malocclusion and extensive attrition, which frequently present in adult patients. Mobility in stages I-II and diminished bony support decrease the anchorage value of the teeth.



**FIGURE 6B.** Panoramic radiograph showing the poor periodontal condition with minimal to moderate bone support. Note also the inclination of the premolars caused by orthodontic extraction at early age and unsuccessful treatment following these extractions.



**FIGURE 6C.** Frontal occlusal view of the Invisalign that was used not only to move the teeth in more controllable method but also to stabilize the mobile teeth while orthodontic movements were performed.



**FIGURE 6D.** Mandibular occlusal view of the Invisalign appliance. Note the full accurate coverage of the whole aspects of the teeth and the esthetic pontic that was used in the anterior region as a temporary restoration until spaces opened properly for implant restorations.

display and the smile: Vertical dimension. *J Clin Ortho* 32: 432-4, 1998.

6. Ackerman MB, Ackerman J, Smile analysis and design in the digital era. *J Clin Ortho* 36(4): 221-36, 2002.

7. Sarver DM, Esthetic orthodontics and orthognathic surgery. St. Louis: Mosby, 1998.

8. Sarver DM, The importance of incisor positioning in the esthetic smile: The smile arc. *Am J Orthod Dentofacial Orthop* 120:98-111, 2001.

9. Scheffan M, Facial and Perioral Rejuvenation, in Romano R, The Art of the Smile: Quintessence publishing, (Germany) 417-28, 2005.

10. Kokich Jr VO, Kiyak HA, Shapiro PA, Comparing the percep-

tion of dentists and lay people to altered dental esthetics. *J Esthet Dent* 11:311-24, 1999.

11. Andrews LE, The six keys to normal occlusion. *Am J Orthod* 62:296-309, 1972.

12. Blake M, Bibby K, Retention and stability: A review of the literature. *Am J Orthod Dentofacial Orthop* 114(3):299-306, 1998.

13. Diedrich PR, Orthodontic procedures improving periodontal prognosis. *Dental Clin North Am* 40(4):875-87, Oct. 1, 1996.

**TO REQUEST A PRINTED COPY OF THIS ARTICLE, PLEASE CONTACT** Rafi Romano, DMD, MS, 34 Habarzel St., Tel Aviv 69710 Israel; romano@shani.net.