

Reconstruction Of Function And Aesthetics Of The Maxillary Anterior Region: A Combined Periodontal/Orthodontic Therapy

Rafi Romano, DMD, MSc
Cobi J. Landsberg, DMD

Severe cases of periodontal disease often require periodontal surgery. Techniques have been developed attempting to minimize the postsurgical gingival recession and compromise of the interdental papillae. This article presents a case report in which soft tissue regenerative surgery was minimized through combined utilization of periodontal and orthodontic principles. The treatment plan included the control of periodontal inflammation, restoration of lost attachment apparatus, realignment of anterior dentition, and stabilization of occlusion. The anticipated loss of a maxillary central incisor was avoided. The learning objective of this article is to present the advantage of the interdisciplinary form of therapy in such challenging cases.

Advanced periodontal disease is characterized primarily by severe attachment loss and reduction of alveolar bony support. The condition usually presents as tooth mobility, migration, spacing, and marginal gingival recession. In the maxillary anterior

Dr. Romano is a Specialist in Orthodontics, Department of Orthodontics, The Hebrew University Hadassah School of Dental Medicine, and the Editor of the Journal of Israeli Orthodontic Society. He maintains a private practice, limited to Orthodontics, emphasizing Adult and Lingual Orthodontics, in Tel Aviv, Israel.

Dr. Landsberg is a Clinical Instructor, Department of Periodontology, The Maurice and Gabriela Goldschleger School of Dental Medicine, Tel Aviv University, and a diplomate of the American Board of Periodontology. He maintains a private practice, limited to Periodontology and Implantology, in Tel Aviv, Israel.

Address correspondence to:

Rafi Romano, DMD, MSc
11a Pinhas Rosen
Tel Aviv 69512, Israel

Tel: 011-972-3-647-7878
Fax: 011-972-3-647-7646

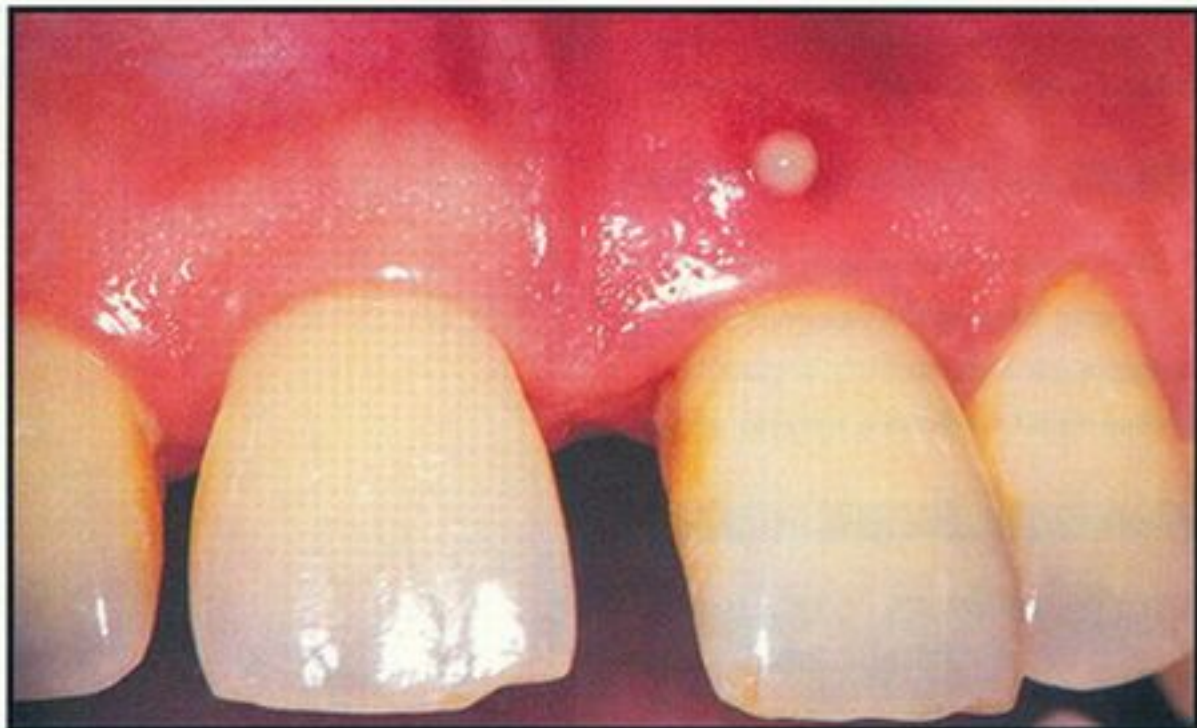

Figure 1. Preoperative facial view of maxillary incisors. Note discharge-secreting fistula associated with periodontal abscess of the maxillary left central incisor.

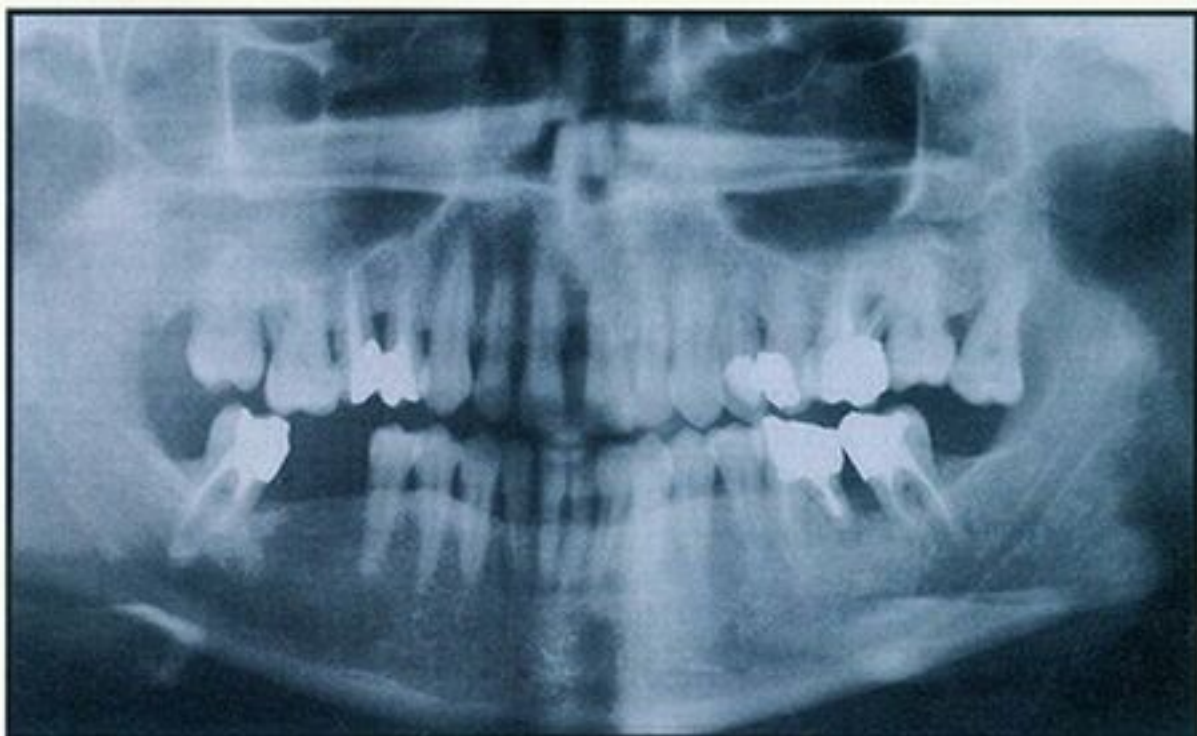

Figure 2. Preoperative panoramic radiograph. Note generalized moderate to advanced bone loss.

region, the functional damage is usually accompanied by compromised aesthetics. Therapy of advanced periodontal cases often requires periodontal surgery, frequently resulting in additional gingival recession and aesthetic deterioration. Since the 1960s, several surgical techniques have been developed to minimize postsurgical gingival recession and preserve the interdental papillae.¹⁸ These techniques are specified by the effort to prevent unnecessary excision of healthy gingival tissue, minimize flap elevation, prevent reduction of bony tissue, and locate the flaps as far coronally as possible by advanced flap manipulation and suturing techniques.

Orthodontic treatment for realignment of migrated periodontally involved teeth is initiated only after control of periodontal inflammation has been achieved.⁹ The timing of the initiation of

Therapy of advanced periodontal cases often requires periodontal surgery, often resulting in gingival recession and aesthetic deterioration.

orthodontic treatment following periodontal surgery is controversial. A long healing period and radiographic evidence of bone apposition are required prior to initiation of orthodontic tooth movement.²⁰ This article presents a modified periodontal/orthodontic approach that was applied for restoration of function and aesthetics in a maxillary anterior dentition, severely compromised by periodontal disease. The purpose of this article is to familiarize the reader with this periodontal/orthodontic approach and its clinical application.

CASE PRESENTATION

A 41-year-old female patient presented with pain associated with a severely mobile maxillary left central incisor; the patient's medical history was noncontributory. The patient anticipated the removal of the incisor and expressed a wish to restore function and aesthetics of the maxillary anterior dentition. Clinical examination revealed large diastemata in the

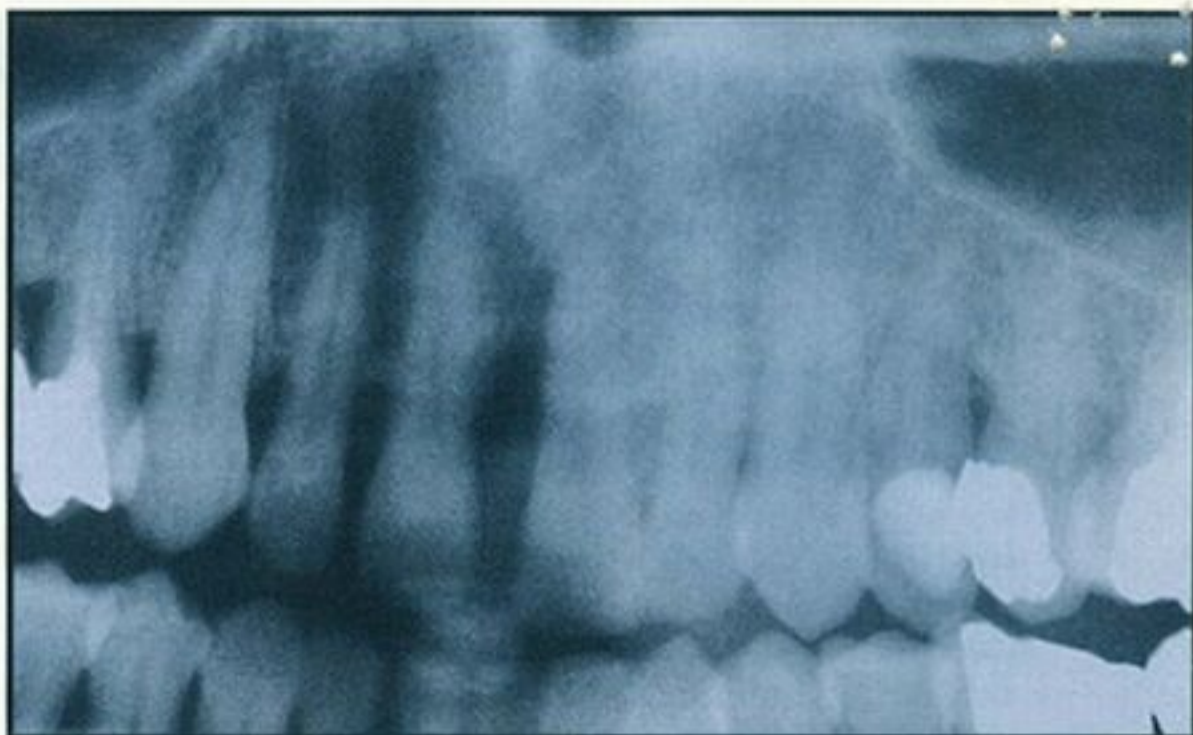

Figure 3. Preoperative close-up radiograph of the maxillary left central incisor. Note the intrabony defect reaching almost to the apex of the tooth.

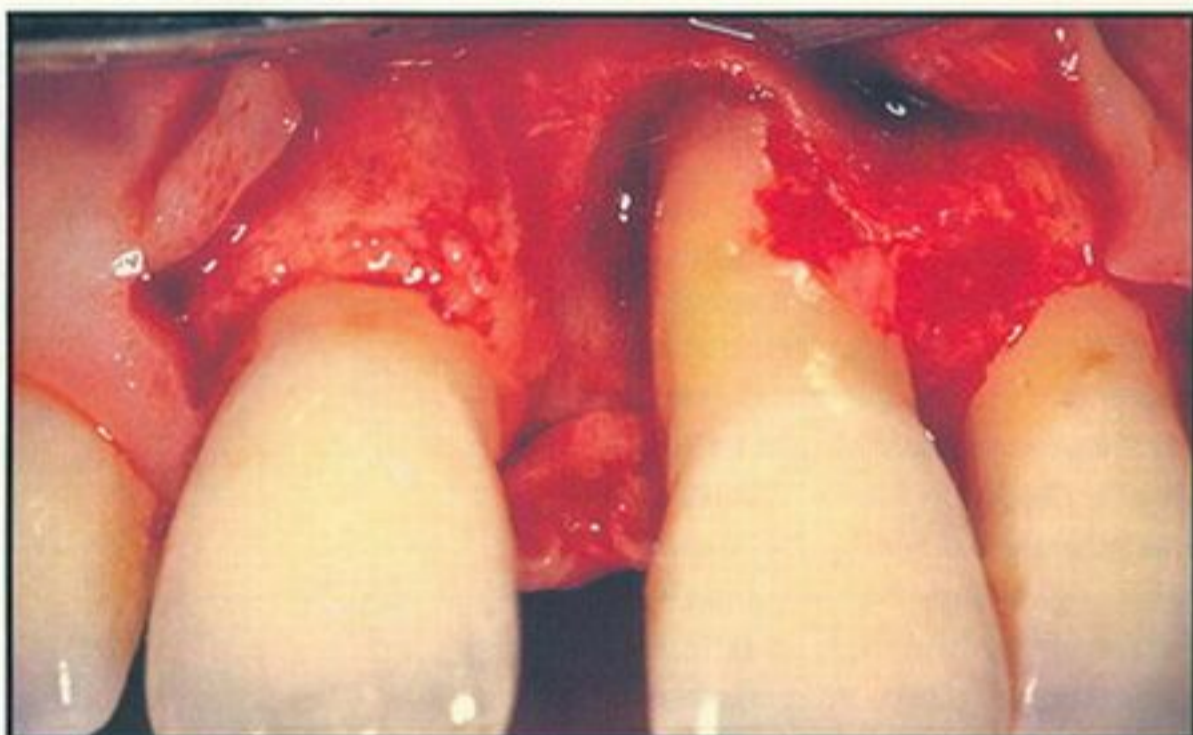


Figure 4. Flap elevation following root planing and bony defect degranulation. Note circumferential bony defect with severe loss of labial plate and interproximal bone.

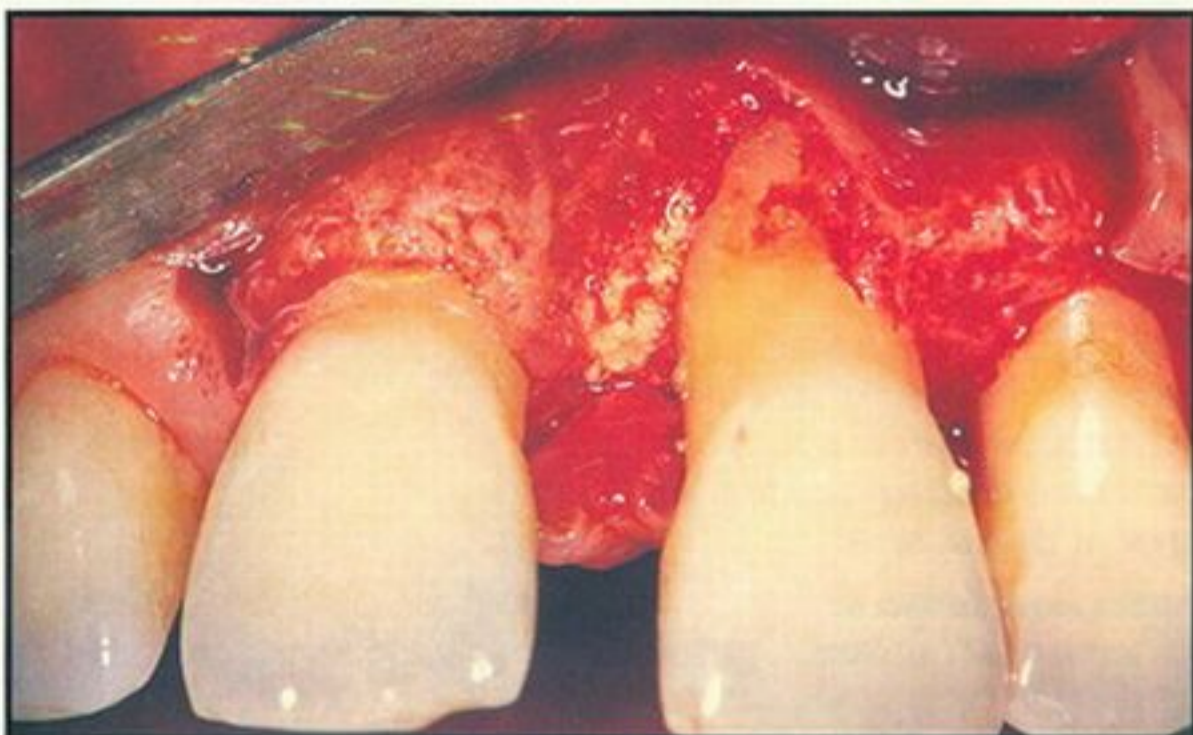


Figure 5. Decalcified freeze-dried bone (DFDB) grafted in the contained part of the bony defect.

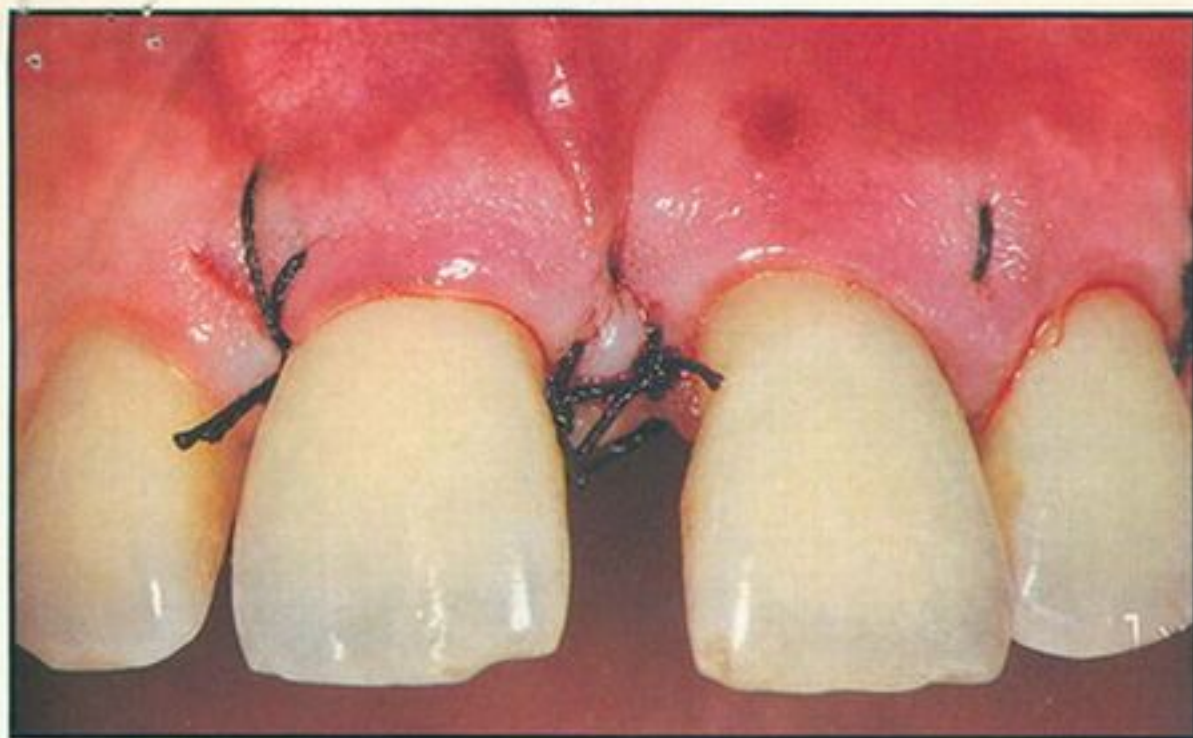


Figure 6. Facial view of vertical mattress sutures combined with simple sutures to "hermetically" close the wound.

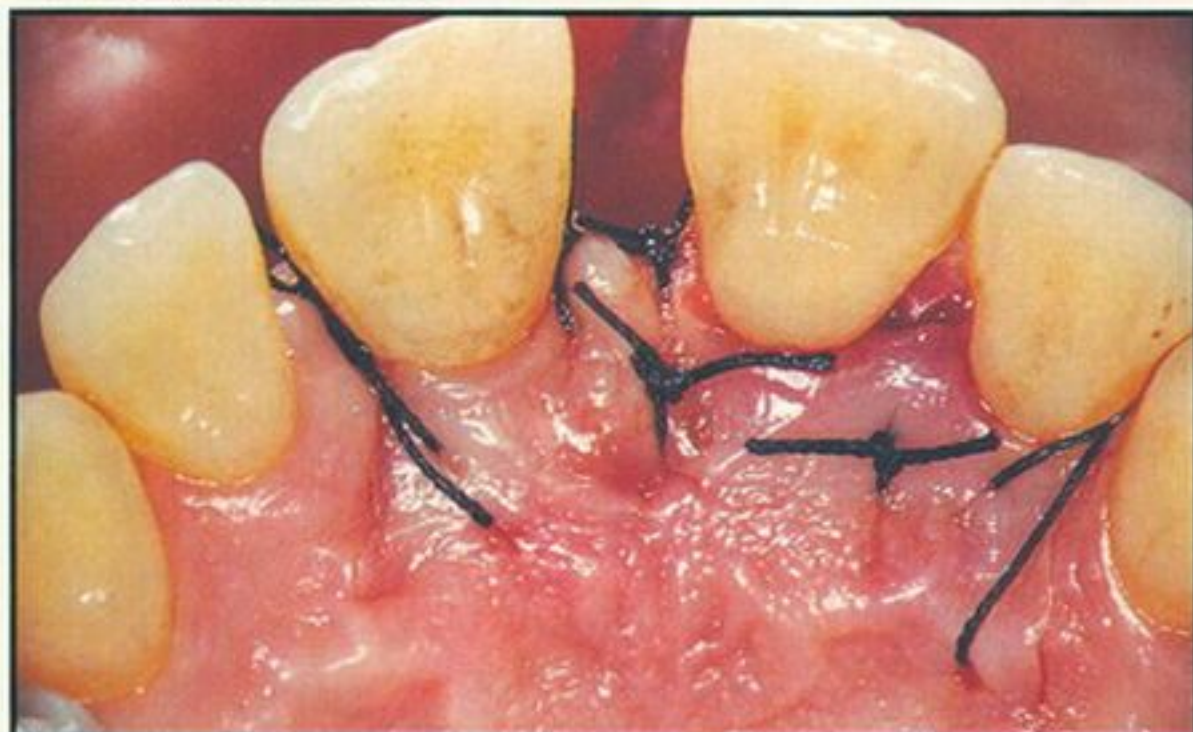


Figure 7. Palatal view of the sutures. "Hermetic" sutures maintain interdental sealing of the wound and papillary height.

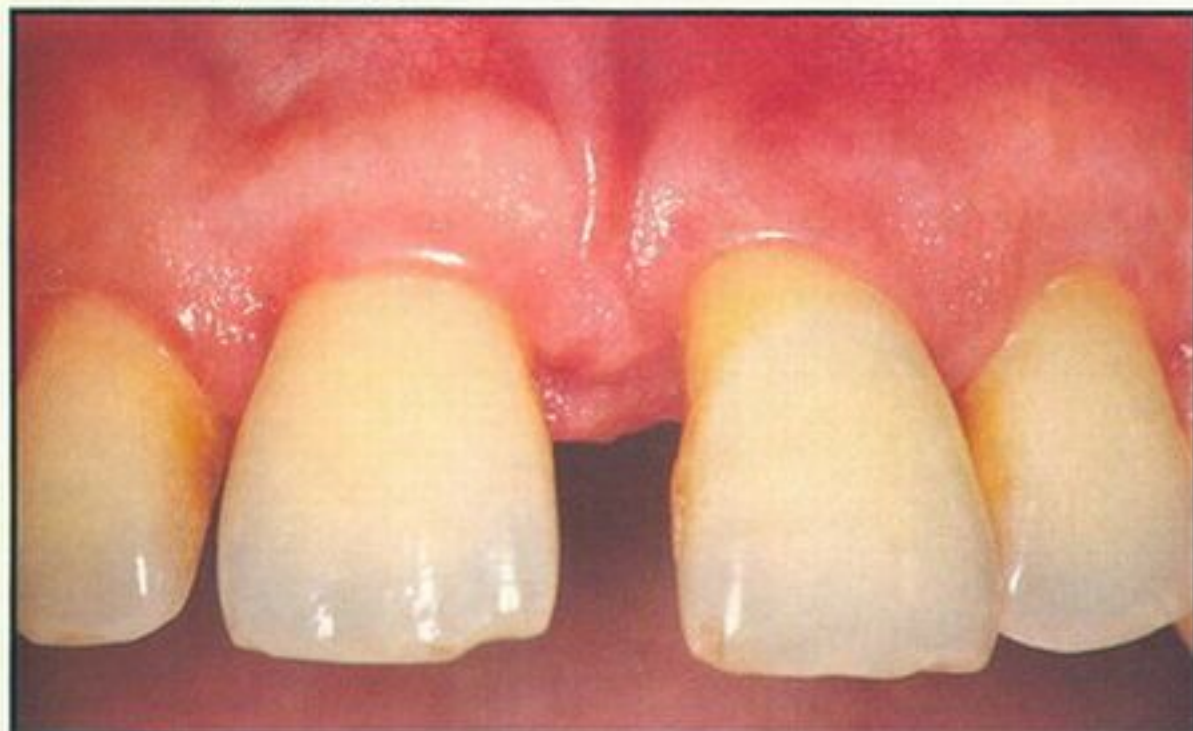

Figure 8. Six weeks postsurgery. Note health of interdental papilla and wound closure. Recession on labiomésial aspect of #9 is due to surgical elimination of granulated tissues.

maxillary and mandibular anterior regions with labial inclination and increased mobility (Grade II), primarily of the maxillary left central incisor. A draining fistula was located at the labial aspect of this tooth (Figure 1). Generally, probing pocket depths ranged from 4 mm to 7 mm, with a 16 mm pocket on the mesial aspect of the maxillary left central incisor and 8 mm on the labiomésial aspect. Radiographic examination revealed generalized moderate bone loss with a severe vertical bone defect on the mesial aspect of the maxillary left central incisor (Figures 2 and 3).

The case was diagnosed as generalized advanced adult periodontitis, accompanied by secondary occlusal traumatism. Prognosis of the case was good, except for the maxillary left central incisor, which was categorized as having poor prognosis. Upon discussing the op-

Orthodontic treatment is initiated only after control of periodontal inflammation has been achieved.

tions, the patient agreed to undergo periodontal and orthodontic therapies in an effort to restore function and aesthetics without the removal of the incisor. The objectives of therapy were to:

- Relieve patient discomfort and pain.
- Control periodontal inflammation.
- Restore lost attachment apparatus.
- Realign the anterior dentition.
- Harmonize and stabilize occlusion.
- Restore aesthetics.

CLINICAL PROCEDURE

The treatment was initiated by temporary splinting of the maxillary left central incisor to the lateral incisor, since the mobility of the central incisor was expected to increase and interfere with the healing process following periodontal surgery. Full mucoperiosteal labial and palatal flaps were elevated between the right central and left canine, using vertical release incisions and taking care to preserve all healthy gingival tissues.

Following root planing and thorough debridement of the bony defect (Figure 4), demineralized freeze-dried bone (DFDB) particles, mixed with tetracycline powder (ratio 6:1), were gently grafted in the contained area of the defect (Figure 5). The flaps were replaced and carefully approximated to "hermetically" isolate the healing wound, using vertical mattress sutures (Figures 6 and 7). Wound isolation and protection by the flaps was successfully maintained throughout a healing period of 6 weeks (Figures 8 through 10), at which time orthodontic treatment was initiated.

Transparent brackets were bonded to the maxillary and mandibular arch. The anchorage was enforced by splinting the posterior segments with temporary bridges. Only light forces (approximately 50 g on each tooth) were applied during the retraction of the anterior teeth.

The aesthetic appearance of the maxillary anterior dentition is determined by the ... labial gingiva and the interdental papillae.

Due to labial inclination of the teeth, only round wires were used to allow tipping of teeth with minimal friction between the wires and the brackets. During the orthodontic treatment (Figures 11 and 12), the patient was re-motivated and periodontally maintained by the dental hygienist on a monthly basis. The fixed appliance was debonded after 11 months, and the teeth were splinted with braided wire, bonded with a composite resin (Figures 13 and 14).

At the completion of active treatment, clinical examination revealed a well-functioning anterior dentition, natural in appearance and in a harmonious occlusion and periodontal state of health (Figures 15 through 18). Radiographic examination revealed favorable root/crown ratio, no signs of occlusal traumatism, dense crestal osseous profiles, and appreciable bone fill in the grafted intrabony defect (Figures 19 and 20). Patient cooperation in maintenance of oral hygiene has been excellent, and

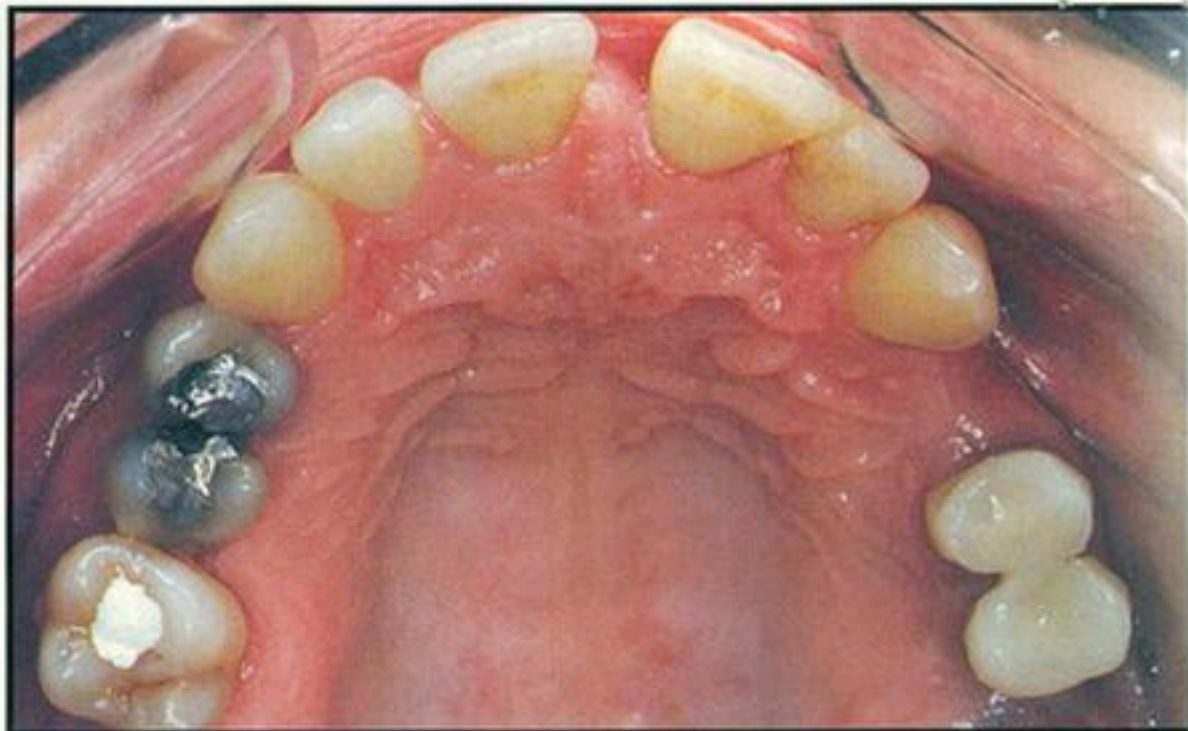


Figure 9. Occlusal view of the maxillary arch at orthodontic examination.

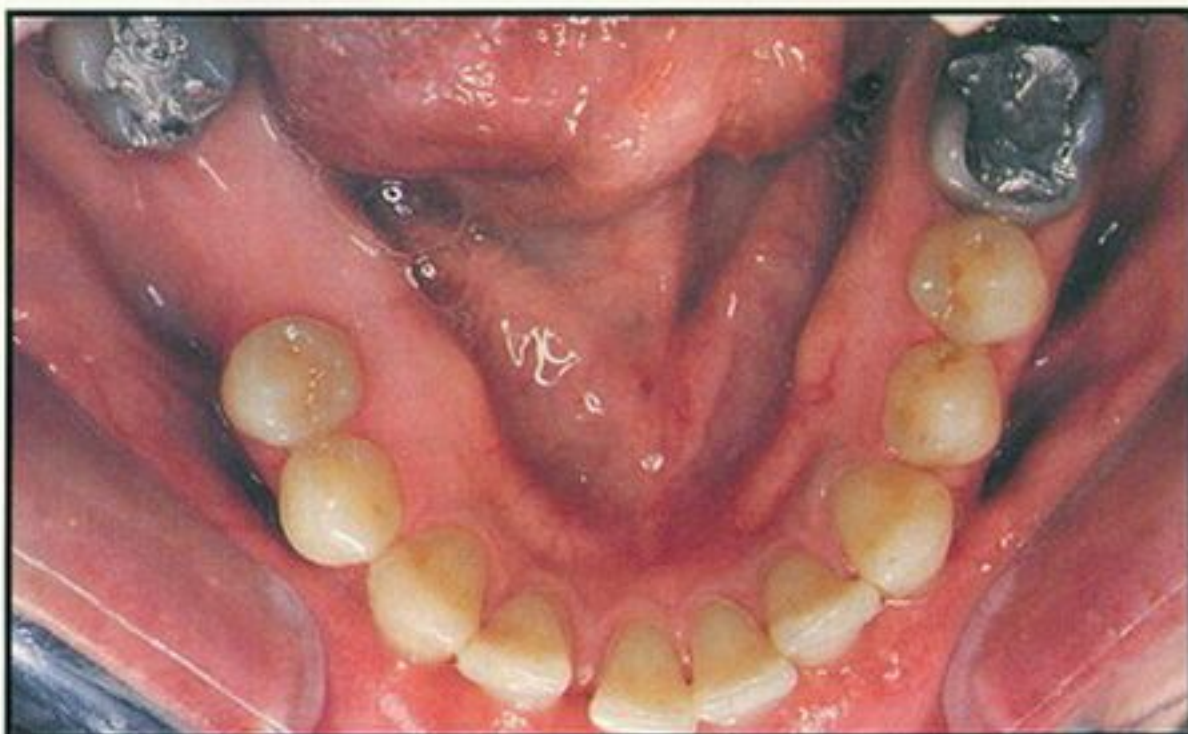


Figure 10. Occlusal view of the mandibular arch at orthodontic examination.

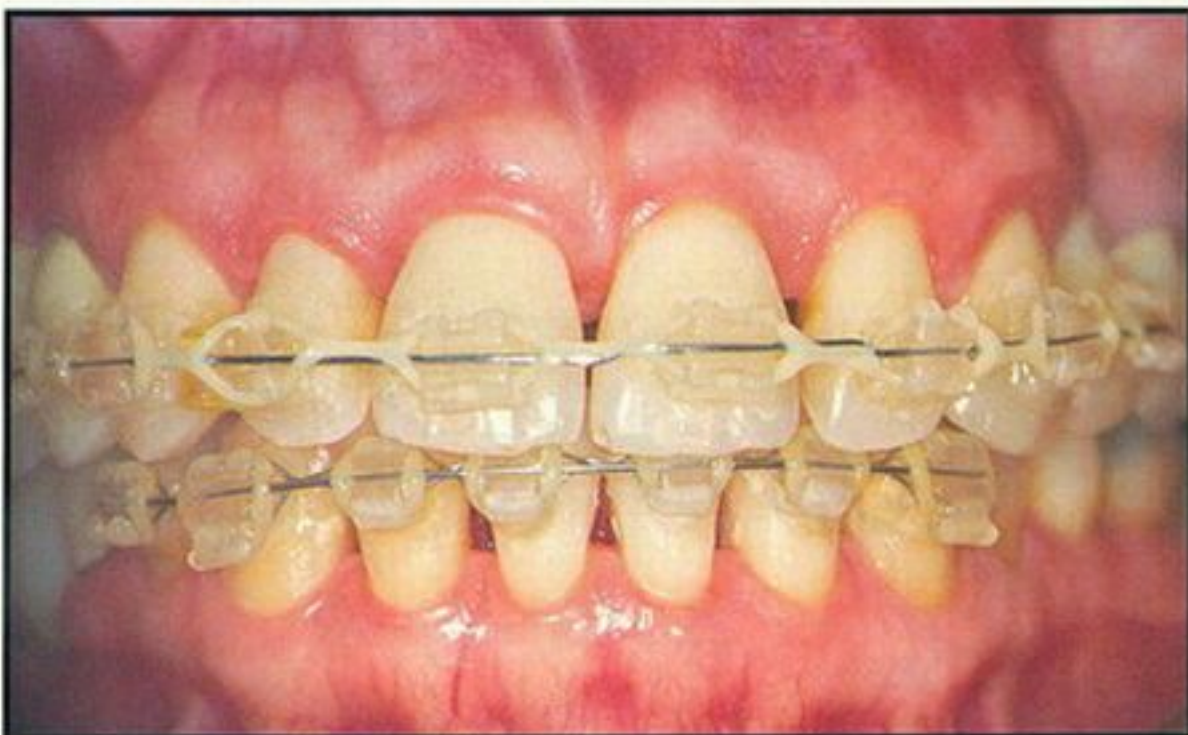

Figure 11. Facial anterior view with orthodontic treatment nearly completed.

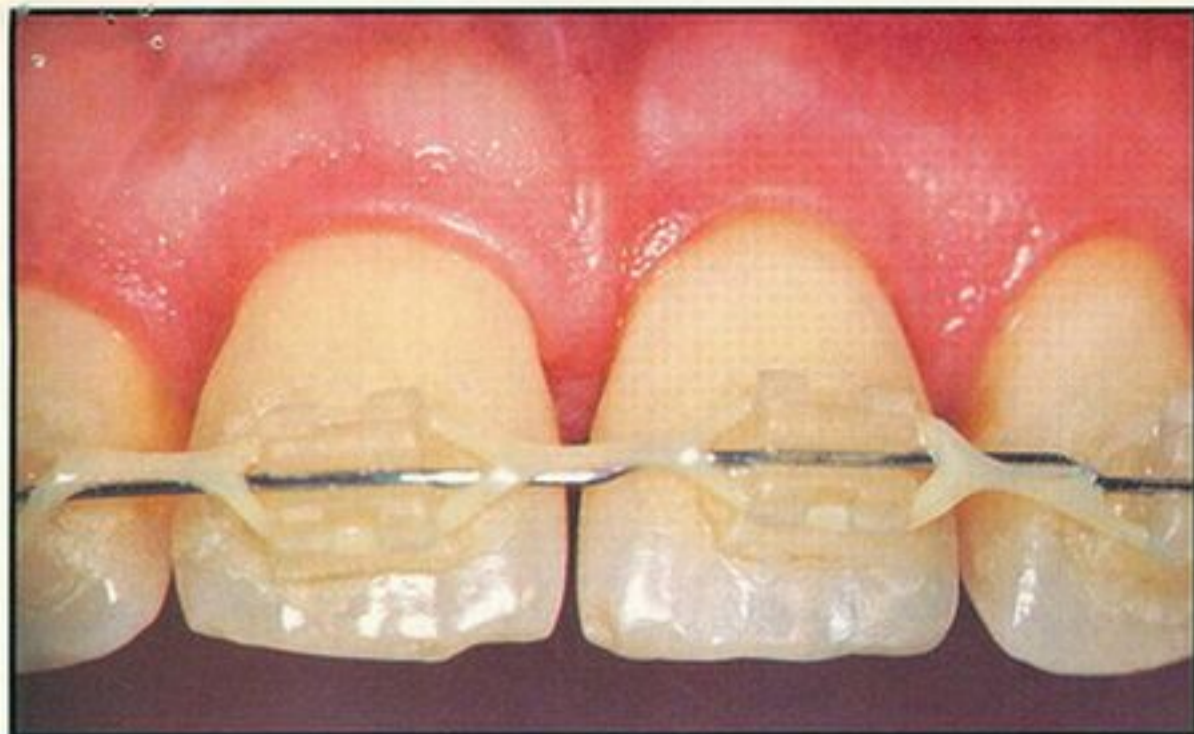


Figure 12. Facial close-up view of maxillary incisors at near completion of orthodontic treatment. Note reformation of interdental papilla and labial gingiva of tooth #9.

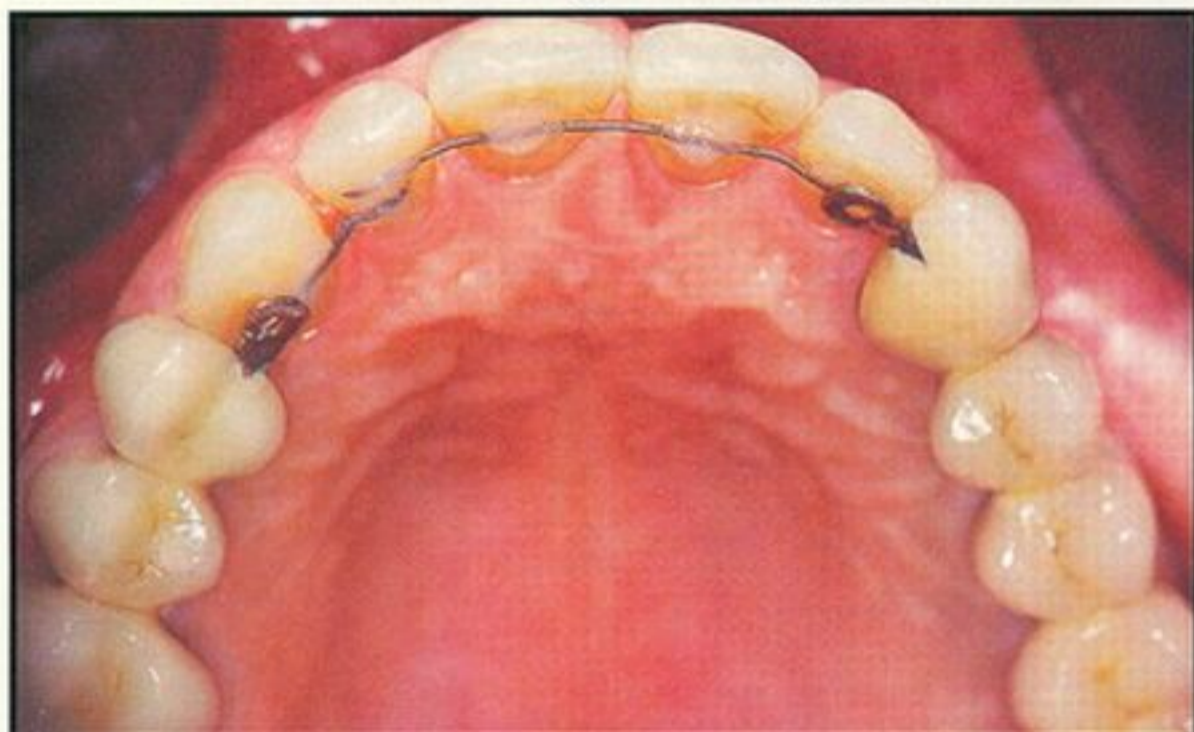


Figure 13. Posttreatment occlusal view of the maxillary arch. Note arch integrity and tissue health.

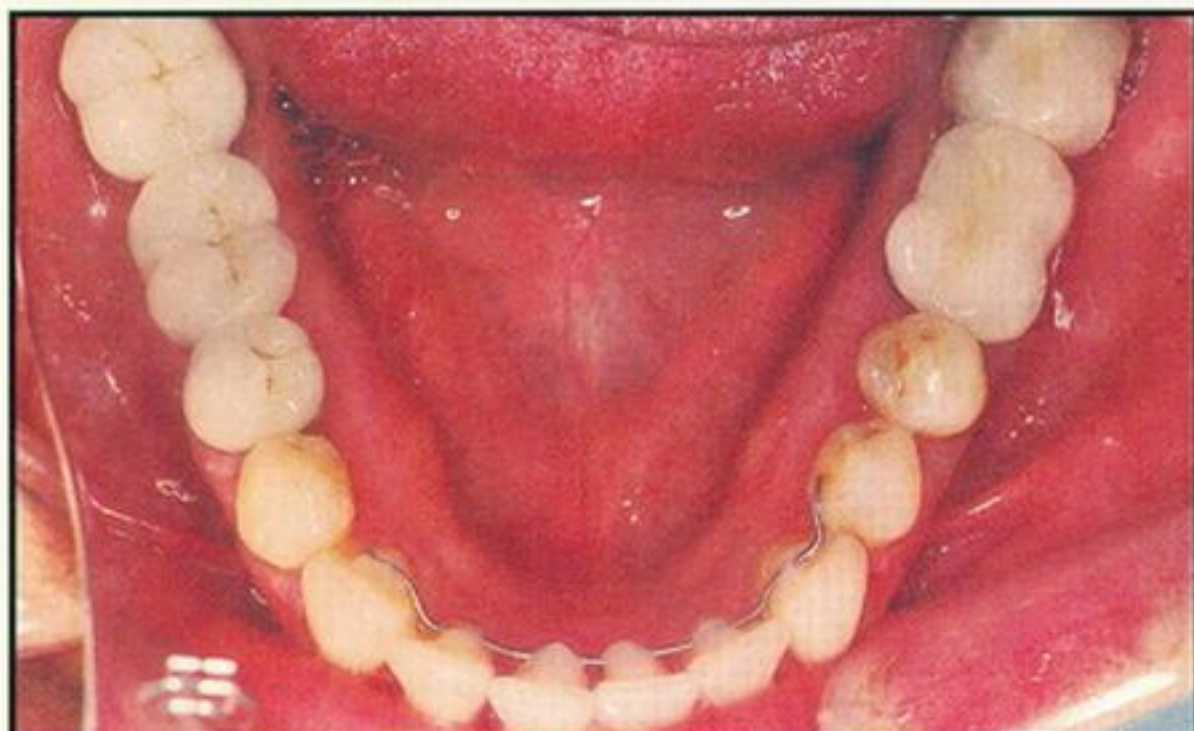


Figure 14. Posttreatment occlusal view of the mandibular arch.

the examination at 18-month post active treatment follow-up revealed that the clinical status and radiographic results observed at the completion of the treatment had been maintained (Figures 21 through 23).

DISCUSSION

The aesthetic appearance of the maxillary anterior dentition is determined to a considerable degree by the contour, size, and health of the labial gingiva and the interdental papillae. The normal contour, shape, and consistency of the gingival tissues, especially of the interdental papillae, may change dramatically with the occurrence and perpetuation of periodontal inflammation. Although a nonsurgical approach is encouraged for the maxillary anterior dentition, there are numerous cases in which the pockets are so deep that proper

The normal contour, shape, and consistency of gingival tissues ... may change dramatically with periodontal inflammation.

and efficient root and gingival curettage may be achieved only by surgical therapy.^{11,12} There also are some instances of intrabony defects, such as presented in this report, which might be grafted preferably either with autogenous bone¹³ or allogeneic bone.¹⁴ To optimize the aesthetic appearance of the periodontally inflamed maxillary anterior dentition, attention should be given not only to the use of advanced periodontal surgical methods but also to proper treatment planning and significant contributions that other disciplines in dentistry may have to offer.

The decision to initiate the treatment immediately with periodontal surgery, prior to orthodontic tooth movement, was based on several clinical factors:

- Acute periodontal abscess is best treated immediately using an open flap approach. Wound repair and tissue regeneration is optimized if

etiologic factors are eliminated during the active "hot phase" of the periodontal disease.^{15,16}

- Control of inflammation is mandatory prior to initiation of tooth movement. In the presence of inflammation, tooth movement may result in significant loss of the attachment apparatus.⁹
- Desirable marginal gingiva alterations following orthodontic tooth movement may be achieved only when the periodontal tissues are in a state of acceptable health.^{17,18}

The surgical flap technique used was similar to those previously suggested.²⁵ Since the deep bony defect of the maxillary left central incisor was localized primarily on the mesial buccal aspect, a rather extensive labial flap was elevated. This significantly improved

Acute periodontal abscess is best treated immediately using an open flap approach.

visibility and the access to the surgical area for meticulous curettage of the diseased root and the bony defect, and for a controlled and adequate execution of the bone grafting process.

Decalcified freeze-dried bone (DFDB) was the grafting material used, due to its osteoinductive or osteoconductive properties.^{19,20} Numerous clinical and histologic studies on the use of DFDB in intrabony defects have demonstrated ample evidence of its superiority over other materials or other surgical modalities.^{19,20} Although being a well-documented and beneficial regenerative surgical modality,^{21,22} GTR had to be excluded to avoid the possibility of complex flap manipulations and risk of membrane infection.

Preservation of soft tissues and use of vertical mattress sutures in the interdental papillary area ensured optimal isolation and protection of the regeneration site and minimal postsurgical gingival and interdental papillae recession.

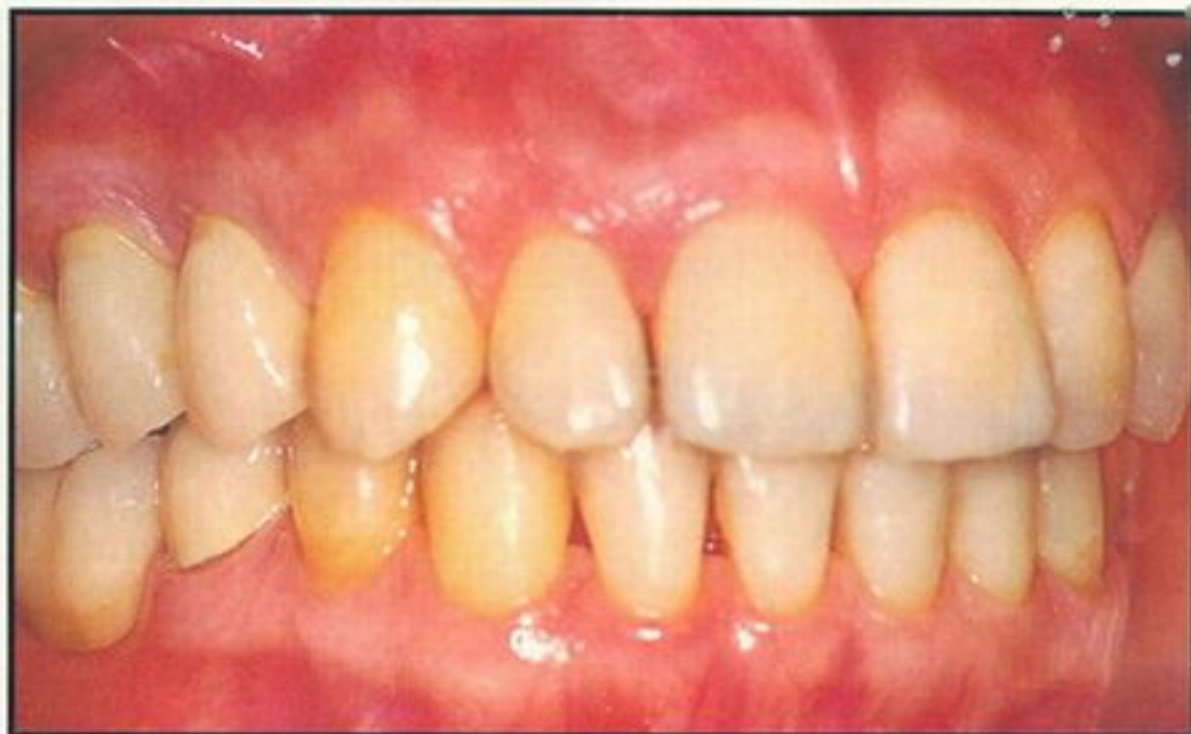

Figure 15. Posttreatment right lateral view. Note arch integrity and tissue health.

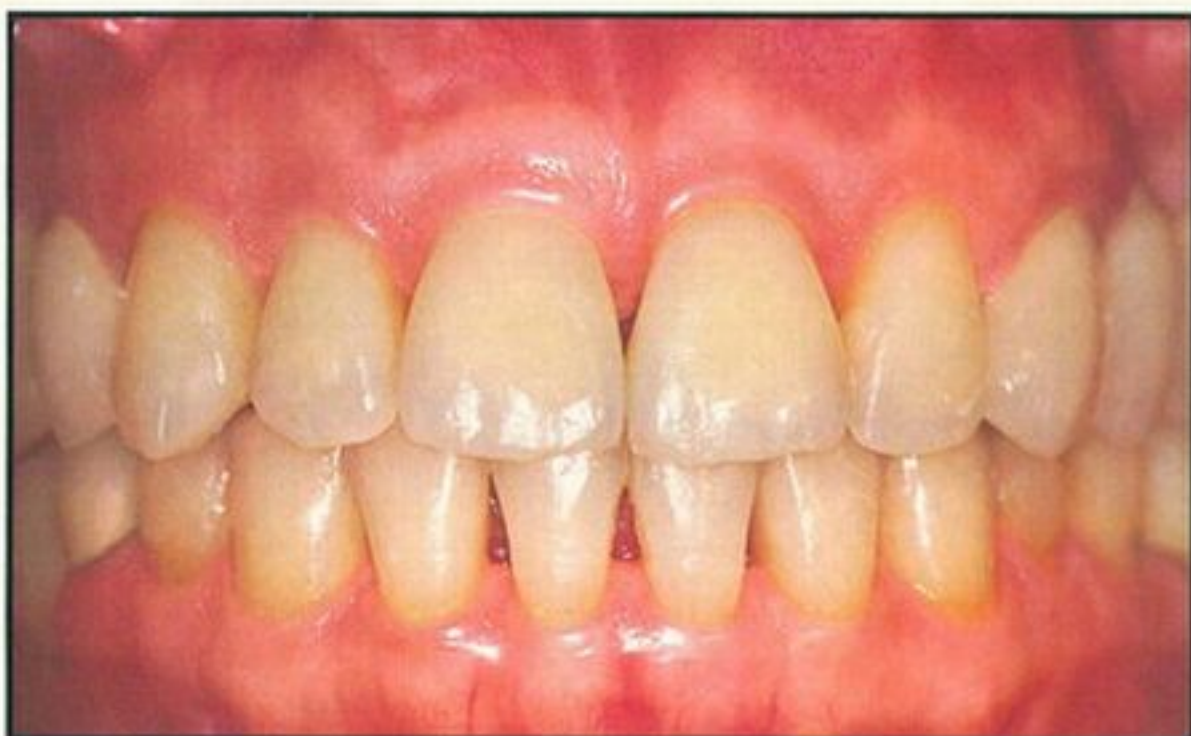

Figure 16. Posttreatment facial anterior view. Note arch integrity and tissue health.

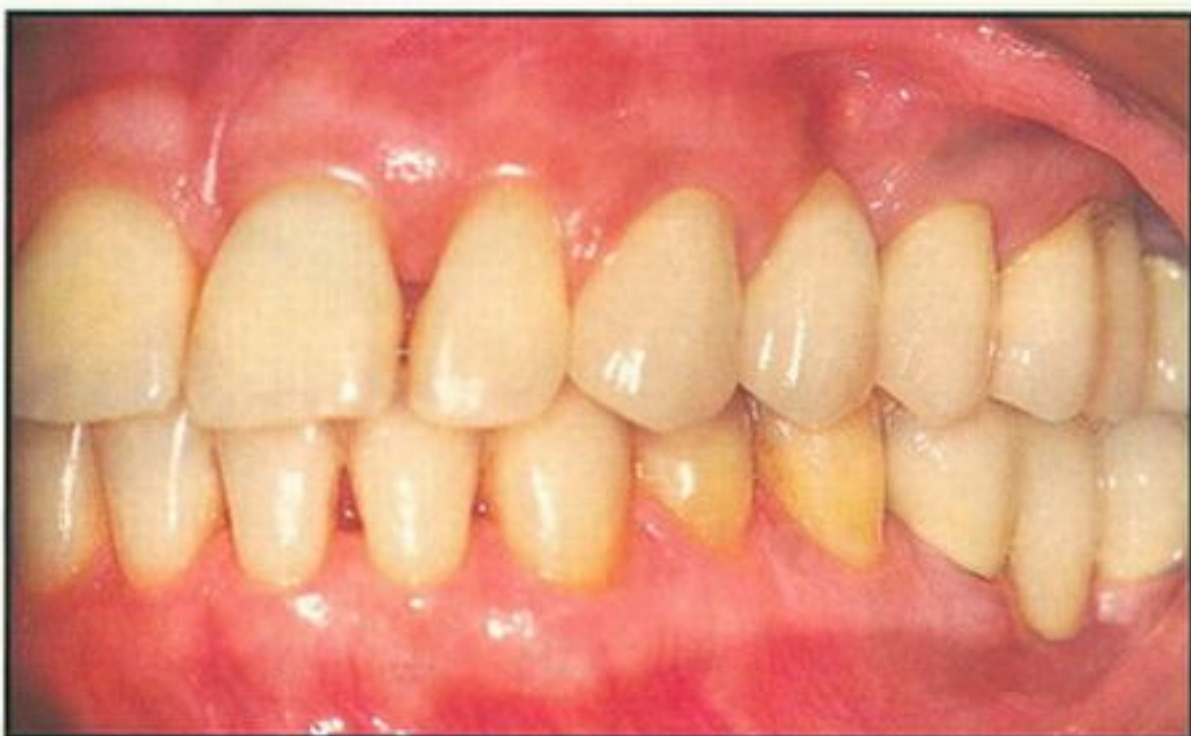

Figure 17. Posttreatment left lateral view. Note arch integrity and tissue health.

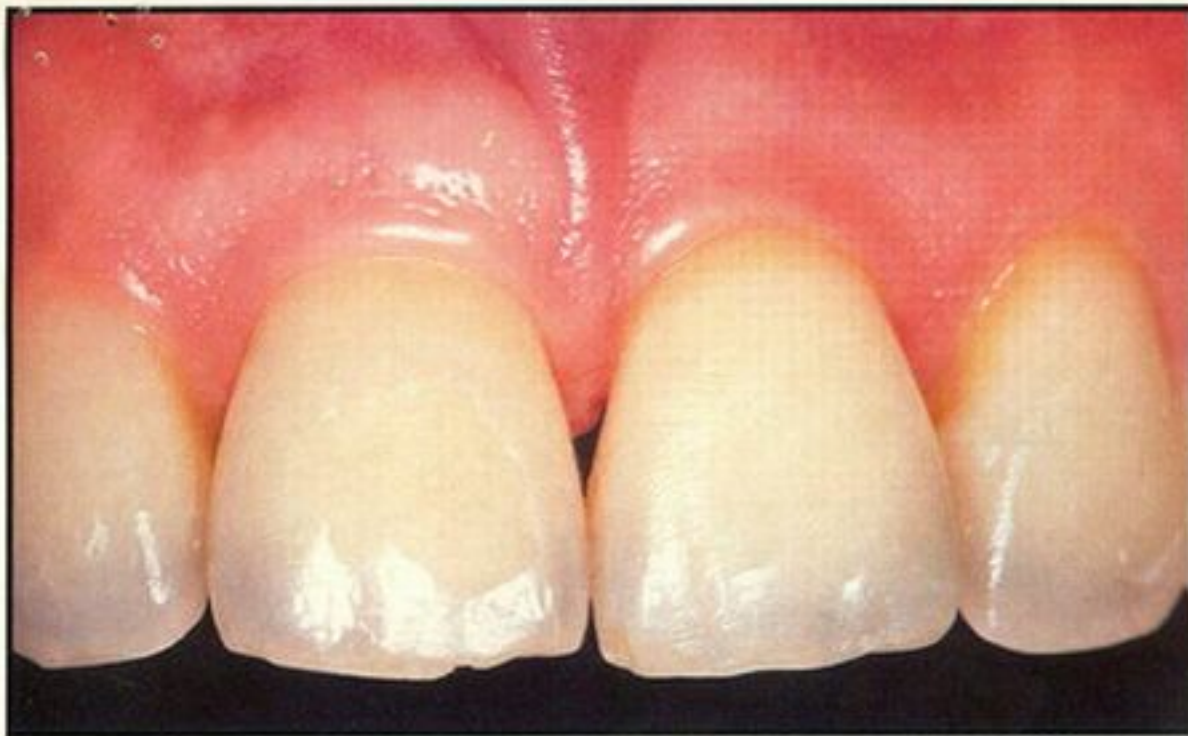

Figure 18. Facial close-up view of maxillary incisors. Note normal gingival height and architecture.

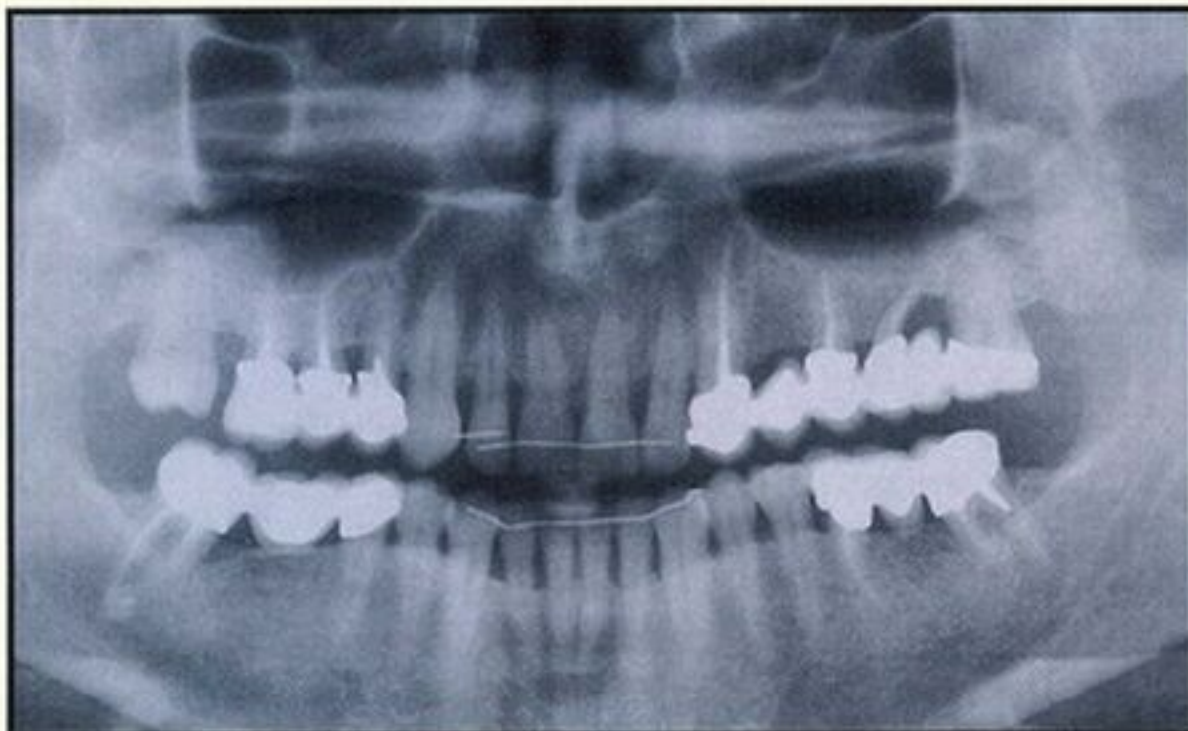


Figure 19. Posttreatment panoramic radiograph.

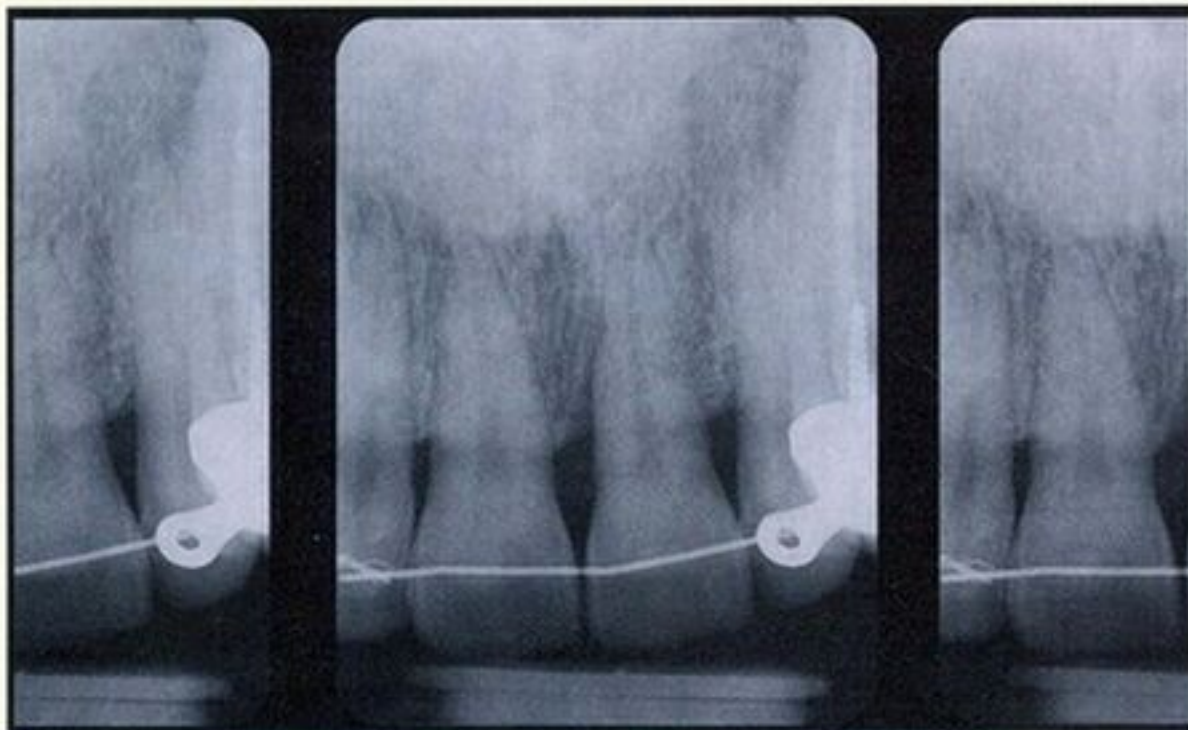


Figure 20. Posttreatment close-up radiograph of the maxillary central incisor region. Note evidence of bone fill with residual vertical, but solid, bone profile.

Preservation and regeneration of the interdental papillae is one of the major treatment objectives clinicians strive to achieve in periodontics^{2,8,23-25} and implantology.²⁶⁻³² In the case presented, preserving gingival margins and interdental papillae could not be achieved solely by the surgical technique. With the understanding that soft tissues move during tooth movement,^{17,18} a periodontal/orthodontic protocol for the maxillary anterior region was planned and rigidly performed to optimize the aesthetic outcome.

Only limited data exist regarding the optimal timing of tooth movement following bone grafting procedures.³³⁻³⁵ In the case presented, no short-term clinical or radiographic evidence was found that contradicted the initiation of orthodontic treatment 6 weeks after the regenerative procedure. However, it is

Tooth intrusion following periodontal surgical therapy may enhance gain of clinical attachment ...

recommended that only light orthodontic forces be used in order to minimize micromovements of the organizing blood clot and optimize the biologic conditions for periodontal regeneration.

Studies have demonstrated the possibility of using minor tooth movement for changing or eliminating bony defects,^{36,37} for increasing the band of attached gingiva,³⁸⁻⁴⁰ for minimizing or eliminating the need for surgical crown lengthening,^{41,42} and for improving aesthetics.^{17,38} Tooth intrusion following periodontal surgical therapy may enhance gain of clinical attachment, providing the biomechanical force system and oral hygiene are maintained.⁴³⁻⁴⁵ This phenomenon is not completely understood, although two possible mechanisms have been suggested:

- The stretching of the periodontal ligament fibers at the marginal level generates a "natural filter," reducing the downgrowth of epithelium.

- Orthodontic stimulation increases the turnover in the periodontal ligament, thereby improving the chances of periodontal ligament cells to repopulate the previously infected root surface.⁴³

The case presented demonstrates not only the gain of clinical attachment and radiographic evidence of bone fill but also significant coronal creeping of the marginal gingiva and almost complete reformation of the interdental papilla between the maxillary central incisors. Therefore, it may be assumed that approximation, retraction, and intrusion of the central incisors collectively resulted in "excess" soft tissue, labially and interdentally, being pushed and stretched in a coronal direction. This periodontal/orthodontic soft tissue



Advanced periodontal/orthodontic treatment ... results in restoration of function and marked improvement in aesthetics.



manipulation, presented by this case, is one way among other nonsurgical techniques^{34,46-48} by which reformation of the marginal gingiva and the interdental papilla may occur, providing periodontal health is maintained.

CONCLUSION

Advanced periodontal and orthodontic treatment may result not only in the restoration of function to the periodontally involved dentition but also a marked improvement in aesthetics. This article demonstrates the value of multidisciplinary interaction in therapeutic treatment and restoration of a severely periodontally compromised dentition to achieve long-lasting functional and aesthetic results.

Acknowledgment

The authors would like to acknowledge prosthodontist A. Eyal, DMD, Holon, Israel, for his work in the case presented.

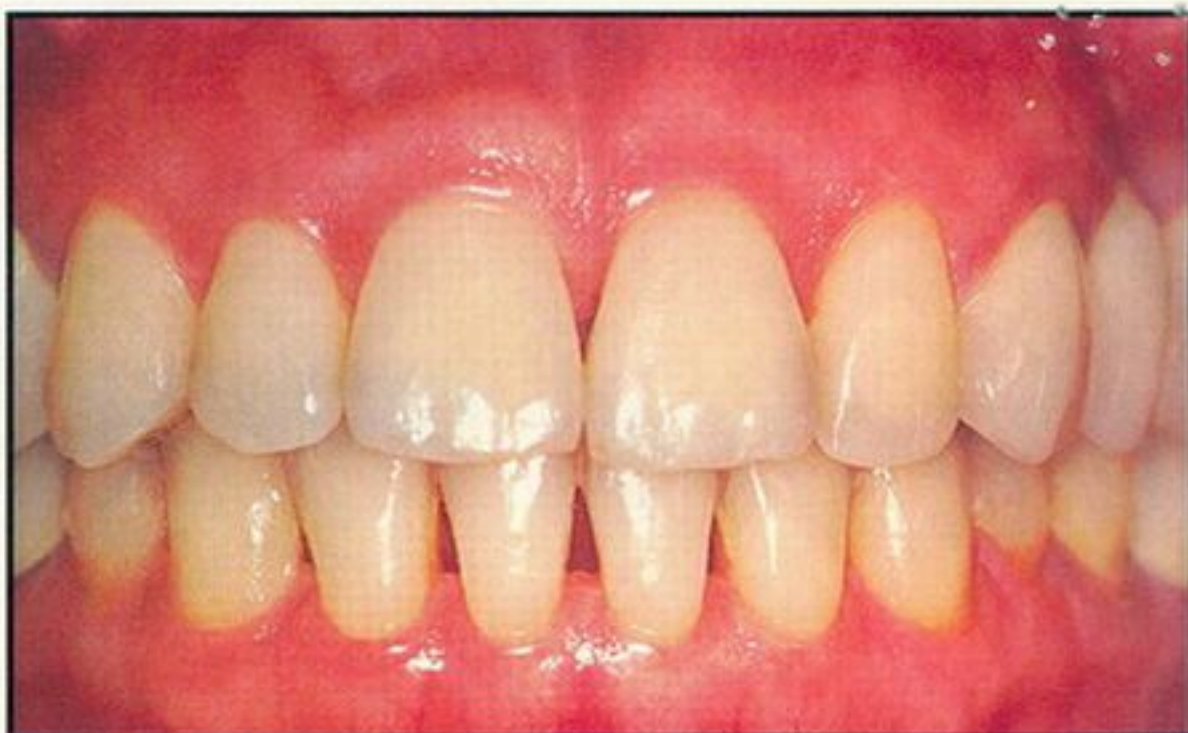

Figure 21. Eighteen-month posttreatment view of the anterior dentition. Note maintained arch integrity and tissue health.

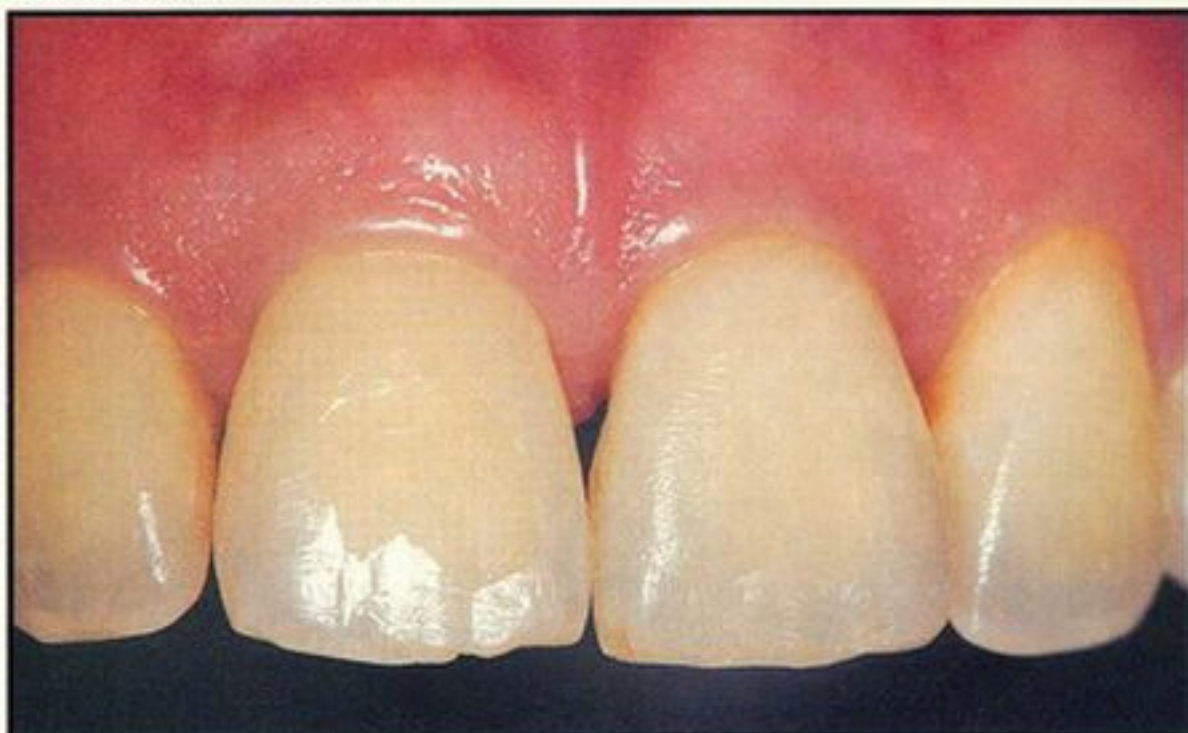


Figure 22. Eighteen-month posttreatment close-up of the maxillary central incisors; facial view.

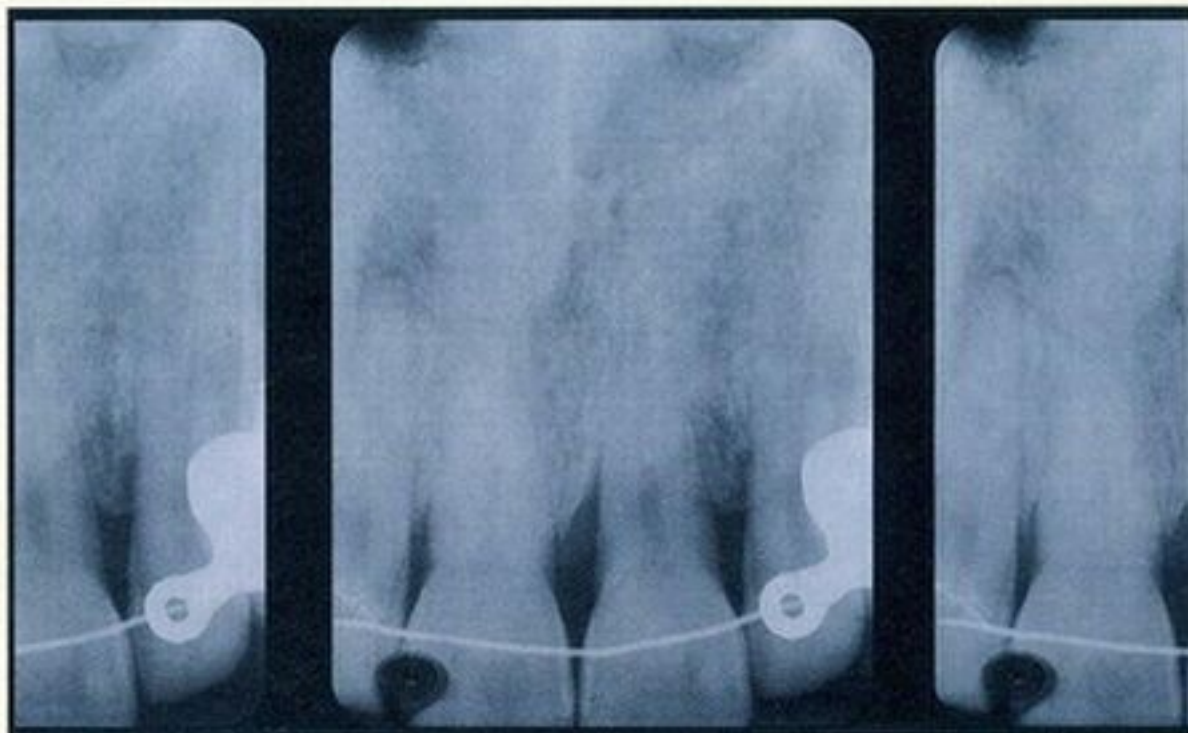


Figure 23. Eighteen-month posttreatment radiograph of the maxillary central incisor region.

REFERENCES

1. Dello-Russo NM. Use of the fiber retention procedure in treating the maxillary anterior region. *J Periodontol* 1981;52:208-219.
2. Evian CI, Cohn H, Rosenberg ES. Retained interdental papilla procedure for maintaining anterior esthetic. *Comp Cont Educ* 1985; 688(1):58-64.
3. Frisch J, Jones RA, Bhaskar SN. Conservation of maxillary anterior esthetics: A modified surgical approach. *J Periodontol* 1967;38:11-17.
4. Levine HL. Periodontal flap surgery with gingival fiber retention. *J Periodontol* 1972;43:91-98.
5. Levine HL, Stahl SS. Repair following periodontal flap surgery with the retention of gingival fibers. *J Periodontol* 1972;43:99-103.
6. Ochslein C, Bohannon HM. The palatal approach to osseous surgery. *J Periodontol* 1963;34:60.
7. Ramfjord SP, Nisile RR. The modified Widman flap. *J Periodontol* 1974;45:601-607.
8. Takei HH, Han TJ, Carranza EA, et al. Flap technique for periodontal bone implants: Papilla preservation technique. *J Periodontol* 1985;56(4):204-210.
9. Marks M. Tooth movement in periodontal therapy. In: Goldman H, Cohen D, eds. *Periodontal Therapy*, 6th Ed. St. Louis, MO: Mosby 1980:565-568.
10. Viazis AD, Corinaiadesi G, Abramson MM. Gingival recession and fenestration in orthodontic treatment: A case report. *J Clin Orthodont* 1990;98:633-636.
11. Rabbani GM, Ash MM, Caffesse RG. The effectiveness of subgingival scaling and root planing in calculus removal. *J Periodontol* 1981;52:119.
12. Kaldhal WB, Kolman FKL, Patil KD, et al. Evaluation of four modalities of periodontal therapy: Mean probing depth, probing attachment level, and recession changes. *J Periodontol* 1988;59:783-788.
13. Hiatt WH, Schallhorn RG, Aronian BJ. The induction of new bone and cementum formation. IV. Microscopic examination of the periodontium following human bone and marrow allograft, autograft, and nongraft periodontal regenerative procedures. *J Periodontol* 1978;49:495-512.
14. Melloni JT. Decalcified freeze-dried allograft as an implant material in human periodontal defects. *Int J Periodont Rest Dent* 1984;4(6):41-55.
15. Prichard JF. *Advanced Periodontal Disease*. 2nd ed. Philadelphia, PA: W.B. Saunders, 1972:604-607.
16. Vence MG, Parma-Benfenati S. Treatment of periodontal abscess: A rationalized approach. *Quint Int* 1984;2:219-227.
17. Ingber JS. Forced eruption: Alteration of soft tissue cosmetics deformities. *Int J Periodont Rest Dent* 1989;9:417-425.
18. Salama H, Salame M. The role of orthodontic extrusive remodeling in the enhancement of soft and hard tissue profiles prior to implant placement: A systematic approach to the management of extraction site defects. *IJPRD* 1993;13(4):312-333.
19. Rommelhart JM, Melloni JT, Gray JL, Toule HJ. A comparison of freeze-dried bone allograft in human periodontal osseous defects. *J Periodontol* 1989;60:655-663.
20. Bowers GM, Chandross B, Carnavale R, et al. Histologic evaluation of new attachment apparatus formation in humans. III. *J Periodontol* 1989;60:683-693.
21. Becker W, Becker BE. Treatment of mandibular 3-wall intrabony defects with flap debridement and expanded polytetrafluoroethylene barrier membrane. Long-term evaluation of 32 treated patients. *J Periodontol* 1993;64:1138-1144.
22. Minabe M. A critical review of the biologic rationale for guided tissue regeneration. *J Periodontol* 1991;62:171-179.
23. De Lange GL. Aesthetic and prosthetic principles for the single tooth implant procedures: An overview. *Pract Periodont & Aesthet Dent* 1995;7(1):51-61.
24. Ricci G. Soft tissue response to surgical and non-surgical periodontal treatment. *Pract Periodont & Aesthet Dent* 1994;6(7):33-40.
25. Beagle JR. Surgical reconstruction of the interdental papilla: Case report. *IJPRD* 1992;12(2):145-151.
26. Touati B. Improving esthetics of implant-supported restorations. *Pract Periodont & Aesthet Dent* 1995;7(9):81-92.
27. Saadoun AP. Periimplant tissue consideration for optimal implant results. *Pract Periodont & Aesthet Dent* 1995;7(3):53-60.
28. Saadoun AP, Sullivan DY, Krischek M, LeGall M. Single tooth implant: Management for success. *Pract Periodont & Aesthet Dent* 1994;6(3):73-80.
29. Landsberg CJ, Bichacho N. A modified surgical/prosthetic approach for an optimal single implant-supported crown. I. The socket seal surgery. *Pract Periodont & Aesthet Dent* 1994;6(2):11-17.
30. Bichacho N, Landsberg CJ. A modified surgical/prosthetic approach for an optimal single implant-supported crown. II. The cervical contouring concept. *Pract Periodont & Aesthet Dent* 1994; 6(4):35-41.
31. Landsberg CJ. Socket seal surgery combined with immediate implant placement: A novel approach for single tooth replacement. *IJPRD* 1996 (Accepted for publication).
32. Palacci P. Periimplant soft tissue management: Papilla regeneration technique. In: *Optimal Implant Positioning & Soft Tissue Management*, Palacci P, ed. Chicago, IL: Quintessence:59-70.
33. Hala Y, Murakami T, Kajiyama K, et al. Application of calcium phosphate ceramics to periodontal therapy: effects of orthodontic force on repaired bone and hydroxyapatite. Tokyo, Japan: Nippon-Shishubyo-Gokki-Kaishi 1989;31(1):224-234.
34. Sheats RD, Strauss RA, Rubenstein LK. Effect of synthetic bone implants on orthodontic tooth movement. *J Oral Maxillofac Surg* 1991;49(12):1299-1303.
35. Nemcovsky CE, Zubery Y, Artzi Z, Liberman MA. Orthodontic movement following guided tissue regeneration. A pilot study. *J Dent Res* 1995;74(3):963(abstract).
36. Brown IS. The effect of orthodontic therapy on certain types of periodontal defects. *J Periodontol* 1973;44:742-756.
37. Wise RG, Kramer GM. Predetermination of osseous changes associated with uprighting tipped molars by probing. *Int J Periodont Rest Dent* 1983;3(1):68-81.
38. Thilander B, Nyman S, Karring T, Magnusson I. Bone regeneration in alveolar bone dehiscences related to orthodontic tooth movement. *Eur J Orth* 1983;5(2):105-114.
39. Batenhorst KF, Bowers GM, Williams JE. Tissue changes resulting from facial tipping and extrusion of incisors in monkey. *J Periodontol* 1974;45:660-668.
40. Coatoam GW, Behrens RG, Bissada NF. The width of keratinized gingiva during orthodontic treatment: Its significance and impact on periodontal status. *J Periodontol* 1981;52(6):307-313.
41. Kozlowski A, Tal H, Lieberman M. Forced eruption combined with gingival fibrotomy. A technique for clinical crown lengthening. *J Clin Periodontol* 1988;15:534.
42. Pontoriero R, Centenza F Jr, Ricci G, Cornevale G. Rapid extrusion with fiber resection: A combined orthodontic-periodontic treatment modality. *Int J Periodont Rest Dent* 1987;7(5):31-43.
43. Melsen B, Agerbaek N. Can attachment gain be achieved by means of orthodontic measures? *Prokt-Kieferorthop* 1991;5(1):11-16.
44. Melsen B. Periodontal response to orthodontic treatment. *J Periodontol* 1989;60(2):207-213.
45. Melsen B, Agerbaek N, Eriksen J, Terp S. New attachment through periodontal treatment and orthodontic intrusion. *Am J Orthod Dentofac-Orthop* 1988;94(2):104-116.
46. Shapira A. Regeneration of interdental papillae using periodontal curettage. *Int J Periodont Rest Dent* 1985;5:27-33.
47. Daftari F, Bahat O. Prosthetically formulated natural esthetics in implant prosthesis. *Pract Periodont & Aesthet Dent* 1994;6(3):73-80.
48. Bichacho N. Cervical contouring concepts: Enhancing the dentogingival complex. *Pract Periodont & Aesthet Dent* 1996;8(3):241-254.