

REPLACEMENT OF A MUTILATED MAXILLARY INCISOR WITH A SINGLE IMPLANT RESTORATION: A STAGED TREATMENT

Cobi J. Landsberg, DMD* • Nitzan Bichacho, DMD† • Rafi Romano, DMD, MSD‡ • Shlomi Silberstein, CDT§

THE CHALLENGE

Patients are advised to maintain oral health in order to enjoy function and the natural appearance of their dentition for a lifetime. In the event that oral health becomes impaired, clinicians are capable of restoring it through either conservative or sophisticated treatment modalities. This treatment must be based on sound, rationalized clinical evidence and a clear understanding of the biological and physiological processes involved. Dental professionals must also acknowledge their personal limitations and be willing to consult and collaborate with colleagues to solve problems prior to and during patient treatment.

During the course of daily practice, clinicians may be confronted with clinical situations that at first sight might appear extremely difficult to solve. In these cases, the challenge for the operating team is to find the simplest, least invasive yet most predictable manner to restore proper health to a particular patient.

Case Presentation

A 24-year-old female patient was referred to the authors in order to save her maxillary right lateral incisor. The patient's dentist claimed to try to elongate the clinical crown by utilizing a combination of flap surgery and electrosurgery;

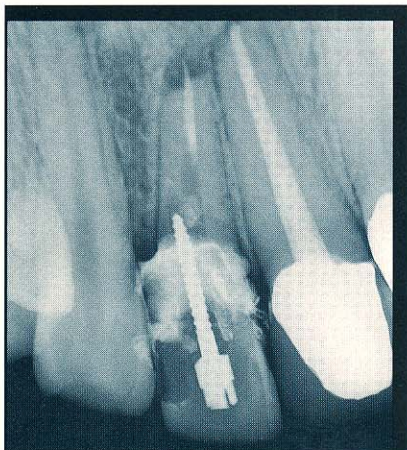


Figure 1. Preoperative radiograph of the lateral incisor revealed a root that had been nearly perforated by a misangulated post. A periapical radiolucency was also evident.

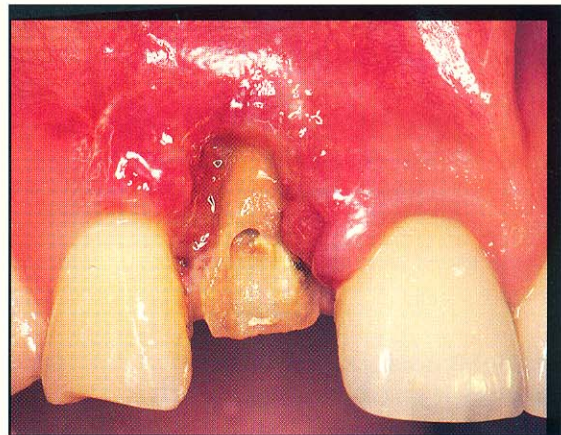


Figure 2. A mutilated tooth associated with extensive soft tissue injury was noted upon clinical examination and crown removal.

this was performed to expose sufficient tooth structure for adequate preparation of the abutment tooth. Since the associated periodontal tissues were severely injured as a result of this procedure, the dentist decided to restore the exposed root with a provisional crown restoration, at which time the patient was referred to the authors.

The tooth was slightly mobile (grade I) and extremely sensitive to palpation. Radiographic examination revealed a root that had been nearly perforated by a misaligned post, periapical radiolucency associated with external apical root resorption, and slight widening of the periodontal ligament space (Figure 1). The mutilated tooth was associated with extensive soft tissue injury (Figure 2).

The prognosis of the tooth was hopeless and it was destined for extraction. Simple extraction of the root at this stage could cause extreme resorption of the soft and hard tissue components of the ridge as well as a resulting functional and aesthetic defect. The challenge was to prevent additional damage to the area and develop an effective treatment plan to reconstruct the lost hard and soft tissues.

*Periodontist, private practice, Tel Aviv, Israel.

†Associate Editor, Practical Periodontics & Aesthetic Dentistry
Private practice, Tel Aviv, Israel.

‡Orthodontist, private practice, Tel Aviv, Israel.

§Dental technician, Oral Design, Tel Aviv, Israel.

THE SOLUTION

Treatment Plan

The objective of treatment was to replace the lateral incisor with an implant-supported crown restoration without interfering with the integrity and topography of the adjacent gingival tissues. In order to develop an adequate implant site, the tooth was planned for orthodontic forced eruption to gain coronal repositioning of the associated gingival tissue.¹⁻³ Due to the impaired attachment apparatus, no coronal gain of crestal bone was anticipated. Following tooth extraction, the ridge would be restored by socket seal surgery and 6 months thereafter an implant would be placed.⁴ Four months postoperatively, second-stage surgery and abutment connection would follow prior to the delivery of the provisional and definitive crown restorations.

Clinical Procedure

Immediately following presentation, the patient received inflammatory control measures and a new provisional acrylic crown restoration that was fabricated chairside. After 1 week, the acute symptoms subsided and the patient was instructed to use 0.2% chlorhexidine gluconate rinses for 1 minute, three times daily, and to begin gentle toothbrushing of the area. Following a 2-week period, orthodontic treatment was initiated.

Orthodontics

Forced eruption of the hopeless tooth was initiated to improve the soft tissue topography of the implant recipient site prior to extraction. A partial orthodontic appliance

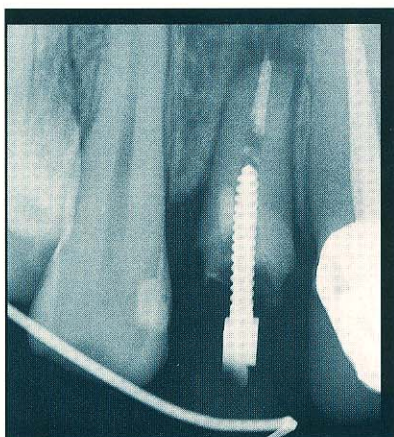


Figure 3. At the conclusion of orthodontic treatment, no significant change was noted in the bony housing of the tooth.

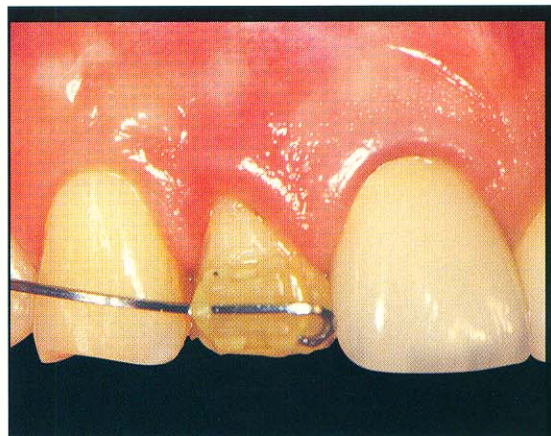


Figure 4. During forced eruption, gingival tissue that has been called "red patch" appeared to move coronally with and over the root surface.

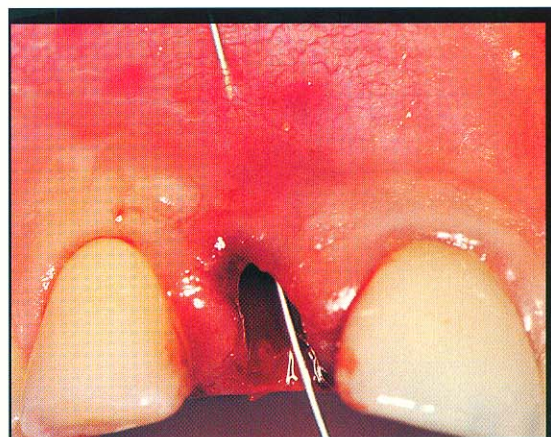


Figure 5. At the initiation of socket seal surgery, the labial cortical plate was entirely absent. The socket was subsequently degranulated and decorticated.

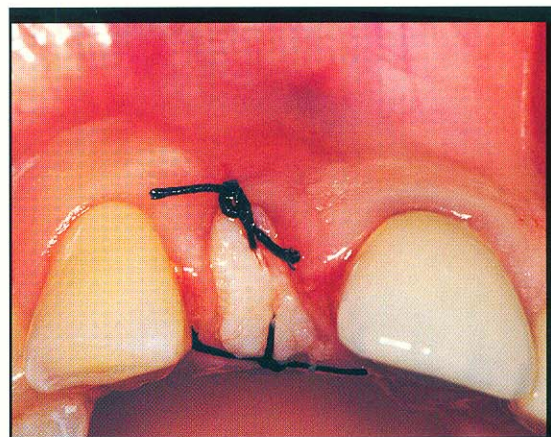


Figure 6. The ovate soft tissue graft was placed to seal the socket orifice and secured with two simple sutures.

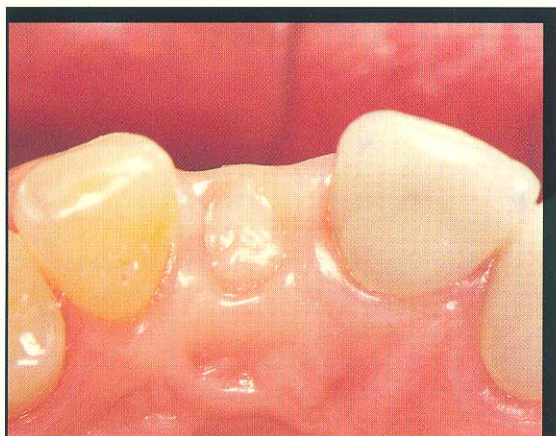

Figure 7. The grafted tissue protected the blood clot during healing, prevented the collapse of the surrounding gingiva, and enhanced the soft tissue topography of the ridge.

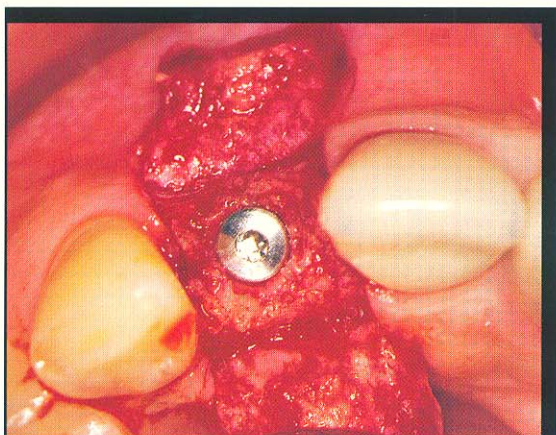


Figure 8. Upon flap elevation 6 months following socket seal surgery, the ridge was found suitable for placement of the implant.

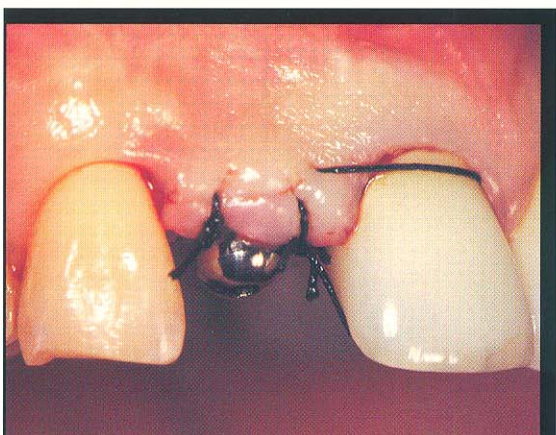

Figure 9. During second-stage surgery, a healing abutment was connected to the implant fixture, and the buccal flap was moved labially to enhance the soft tissue at the implant site.

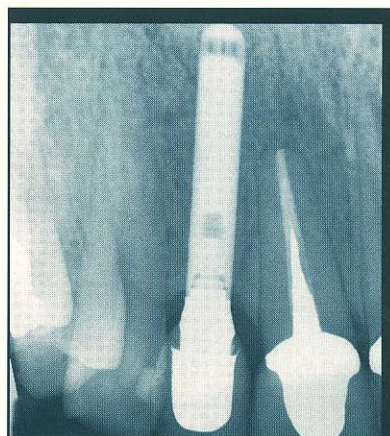

Figure 10. The 2-year postoperative radiograph of the implant demonstrates the integration of the implant fixture within the patient's maxilla.

(Ormco Spirit brackets, 0.022", Sybron International, Orange, CA) was bonded to the maxillary lateral incisor and to the distal teeth for anchorage. Very light extrusive force was applied (0.014" nickel titanium wire). The patient was recalled every 2 weeks for control of inflammation and reduction of the incisal edge to avoid occlusal trauma. As anticipated, the radiographic appearance suggested no significant change in the bony housing of the tooth (Figure 3). During the course of eruption, which lasted 6 weeks, an immature-appearing gingival tissue that has been termed "red patch"⁵ appeared to move coronally with and over the root surface (Figure 4). At 8 weeks, as keratinization of the newly formed gingival margins proceeded, tooth extraction and ridge preservation commenced.

Socket Seal Surgery

The residual root was gently removed without flap elevation to minimize severing of the local vasculature. It was noted that the labial cortical plate was entirely missing (Figure 5). The socket was thoroughly degranulated and the palatal bony wall was decorticated in its apical portion to enhance recruitment of bone-forming cells from the endosteum. The inner face of the gingival walls were de-epithelialized circumferentially with a water-cooled, round diamond bur to create a vascularized recipient bed. Decalcified freeze-dried bone particles, which may exhibit osseoconductive and osteoinductive properties as well as prevent postoperative recession of the labial plate, were gently condensed to fill the socket bony walls. An oval soft tissue graft with a thickness of 3 mm was obtained

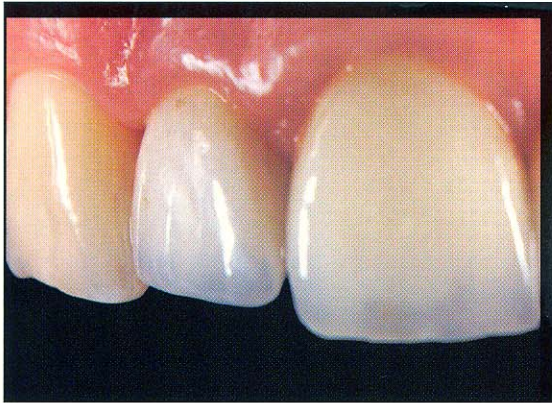

Figure 11. Two-year postoperative view demonstrates the harmony between the definitive Artglass-fused-to-Captex implant-supported restoration and the soft tissues.

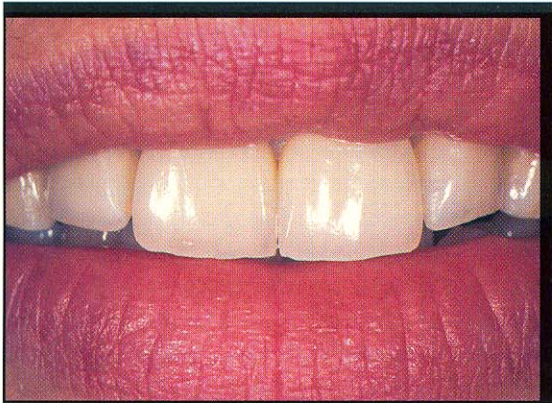


Figure 12. Facial view demonstrates the integration of the implant-supported restoration with the porcelain-fused-to-Captex crowns that were replaced on teeth #8 and #9.

from the palate and placed immediately on top of the bone graft to completely seal the socket orifice.⁴ It was gently adapted to the surrounding vascularized gingival walls by two simple sutures (Figure 6). The grafted soft tissue prevented physical, chemical, or bacterial interference to the organizing blood clot and bone graft during the healing period. It also prevented collapse and shrinkage of the surrounding gingiva and interdental papillae while enhancing the soft tissue topography of the ridge (Figure 7).

Implant Surgery — Stage 1

Six months following socket seal surgery, midcrestal and vertical incisions were made for elevation of labial and palatal miniflaps. The ridge was sound and sufficiently wide for insertion of an appropriately sized implant fixture (Omniloc, Calcitek, Carlsbad, CA) (Figure 8). The flaps were readapted by vertical mattress vicryl sutures. In order to prevent scarring of the gingiva, sutures were not placed on the vertical incision lines.

Implant Surgery — Stage 2

Four months postinsertion, the implant was exposed using a midcrestal incision without releasing incisions.⁶ A healing abutment was connected to the implant, and the buccal flap was repositioned further labially to enhance the soft tissue adaptation at the implant site (Figure 9).⁷

Prosthodontics: Cervical Contouring Concept and Transmucosal Prosthetic Unit Fabrication

An impression of the implant head was taken and transferred to a plaster model, in which the periimplant soft tissues were replicated in acrylic resin which was then carved to an optimal three-dimensional configuration.⁸ A custom-made gold abutment was fabricated accordingly; the interproximal margins followed the designed papillae of the model.⁷ A provisional crown restoration was fabricated and fitted in the laboratory, as was a gold composite alloy coping (Captex, Precious Chemicals, Longwood, FL).

Due to the patient's request to enhance her aesthetic appearance, the existing crowns on the central incisors were replaced with porcelain-fused-to-Captex crown restorations. Once abutment connection had been completed, the fit of the gold composite alloy coping was verified intraorally and picked up with an elastomeric impression material. The provisional acrylic crown restoration was provisionally cemented. Repositioned on a new plaster model, the coping was veneered with polymer glass material (Artglass, Jelenko, Armonk, NY); the margins of the restoration were fabricated from the veneering material for an enhanced optical appearance. The Artglass-fused-to-Captex crown restoration was then connected to the abutment to create a satisfactory, functional, and aesthetic result (Figures 10 through 12).

References

1. Ingber JS. Forced eruption: Part 1. *J Periodontol* 1974;45:199-206.
2. Ingber JS. Forced eruption: Part 2. *J Periodontol* 1976;47:203-216.
3. Salama H, Salama M. The role of orthodontic extrusive remodeling in the enhancement of soft and hard tissue profiles prior to implant placement. *Int J Periodont Rest Dent* 1993;13:312-334.
4. Landsberg CJ, Bichacho N. A modified surgical/prosthetic approach for optimal single implant supported crown. Part I — The socket seal surgery. *Pract Periodont Aesthet Dent* 1994;6(2):11-17.
5. Mantzikos T, Shamus I. Forced eruption and implant site development: Soft tissue response. *Am J Ortho Dentofac Orthop* 1997;112:596-606.
6. Becker W, Becker BE. Flap designs for minimization of recession adjacent to maxillary anterior implant sites: A clinical study. *Int J Oral Maxillofac Impl* 1996;11(1):46-54.
7. Bichacho N, Landsberg CJ. Single implant restorations: Prosthetically induced soft tissue topography. *Pract Periodont Aesthet Dent* 1997;9(7):745-752.
8. Bichacho N, Landsberg CJ. A modified surgical/prosthetic approach for an optimal single implant-supported crown. Part II — The cervical contouring concept. *Pract Periodont Aesthet Dent* 1994;6(4):35-41.