

Lingual Orthodontics: The ultimate aesthetic orthodontic option of the next millennium

Rafi Romano, Silvia Geron

Rafi Romano DMD, MSc, Specialist in Orthodontics

Private practice, limited to orthodontics, emphasizing adult and lingual orthodontics, editor: Color Atlas of Lingual Orthodontics (B.C. Decker publishing).

Address: 11a Pinhas Rosen, Tel Aviv 69512, Israel.

Tel: 972-3-6477878 Fax: 972-3-647646

Silvia Geron DMD Msc, specialist in orthodontics, maintains a private

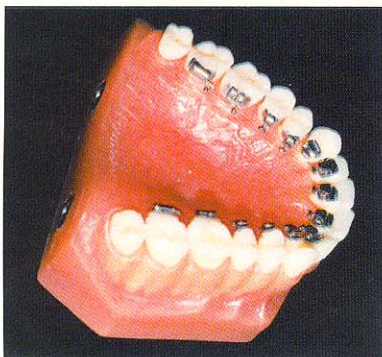
practice limited to orthodontics, emphasizing lingual orthodontics. The inventor of a new method for lingual bonding.

Address: 25 Kazenelson st., Rishon Lezion, Israel.

Tel/Fax: 972-3-9654903

Since early 1970s, when Lingual (invisible) Orthodontics (LO) was first presented by late Dr. Craven Kurz from UCLA School of Dentistry and Dr. K. Fujita from Japan, tremendous changes have occurred. Clinical results have improved and turn out to be as good as labial orthodontics, sometimes even better. Precise laboratory techniques and strong and reliable bonding materials facilitate the treatment for the LO practitioner. Treatment time is shorter due to step by step protocols for every case and less bonding failures. Prices are more reasonable than ever, since many orthodontists and even dentists take LO courses from excellent teachers, all over the world. A text-book has recently been published and congress are held few times a year with outstanding lectures on various topics given by orthodontists who devote their practice only to LO. Demand for aesthetic dentistry is rising all over the world, and LO is the only invisible orthodontics existing today. Still, LO is so small in comparison with labial orthodontics that the major orthodontic suppliers do not want to invest in developing newer brackets, newer pliers etc. In fact, practically all but Ormco have almost completely stopped manufacturing products specifically for Lingual Orthodontics. The extensive media exposure, that was one of the major disadvantages of this treatment modality in the past, when no protocol and no complete cases were available, is so small and unnoticed nowadays, that most dentists and patients do not know that it still exists. Many orthodontists who do not even practice LO and do not know its advantages, claim that it does not work!

This paper is a survey of some of the extensive possibilities and advantages that LO gives to the orthodontist, to the dentist and to the patients.




*The lingual appliance
(Ormco generation 7
brackets)*



Intrusion (1)

Bonding the bracket on the lingual face of the tooth places intrusive forces close to the center of resistance of the tooth. Therefore, it requires lighter force application for tooth movement as compared with labial orthodontics. The bite plane effect of the lingual appliance is always in contact with the lower incisors (unless there is an open bite, where intrusion is not needed), therefore light, continuous, intrusive force is more effective with LO.



Expansion (1)

Clinically, we have noticed that a more remarkable dento-alveolar expansion through lingual mechanics is achieved through LO probably due to lack of posterior contacts. Since the application point of the force is closer and more palatal compared to the center of resistance of the tooth, the outside movement probably takes place without a remarkable tooth labial inclination.

Distalization (1)

Lingual brackets are placed closer to the center of rotation (CR) of the tooth. When the force is applied from the lingual the tooth appears to be displaced distally in a more bodily movement comparing to the rotation we usually have when distalizing with labial orthodontics distalization.

Enamel reproximation (2)

This technique is also known as interproximal reduction or air rotor stripping. The technique, once rarely used, seems to regain favour because of the increased number of adults seeking lingual orthodontic therapy. Adult orthodontics often eliminates treatment options that require cooperation and are not cosmetically acceptable. Adult patients

generally have demanding life schedules; therefore, treatment plans should be designed so as to place fewer additional demands on regular activities, and thus require minimal cooperation.

Simple and highly efficient bonding procedure (3)

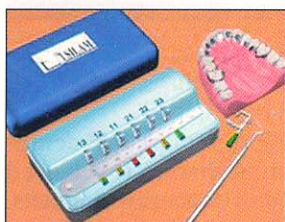
Using two components unfilled resin facilitates bonding procedures, microblasting the lingual enamel, metal fillings or porcelain crowns prior to etching makes bonding more efficient, and creating good and perfectly dry working field makes the bonding more reliable.

Simple mechanics (4)

Shape memory wires in LO are new and are widely used now. Ligating is more easy due to the increased elasticity and the heat activated wires. Less wire changes are needed since the duration of each wire allow the practitioner less appointments and more comfort for the patient.

Laboratory procedures (5,6)

Two main bonding techniques are used now with LO, both of them are done indirectly. One is the thickness measurement system with the DALI (dessin de l'Arc Lingual Informatise) program. An easy accurate lingual indirect bonding system, developed by Dr. Didier Fillion and the CLASS System (Customized Lingual Appliance Set-Up Service), developed by Scot A. Huge: A new method for direct and indirect lingual bracket bonding, the Lingual Bracket Jig (LBJ) was recently invented by DR. Sylvia Geron with practical guidance for direct and indirect bonding. The LBJ is a device for precise positioning of lingual brackets in a prescribed height, torque, angulation and in-out position. The device is very easy to use for direct bonding of lingual brackets, or for in-office indirect bonding, allowing personal control of the bracket positioning by the orthodontist. This new jig will probably enhance interest for LO tremendously since the difficult laboratory procedures are one of the main reasons for orthodontists to avoid using lingual appliances.



The Lingual Bracket Jig

Speech/Pain Problems (7)

Recent clinical surveys, carried out by Dr. Didier Fillion in his office (JCO), indicate clearly that most patients get used to their appliance in 2-4 weeks, without any remaining of speech problems or other disturbance.

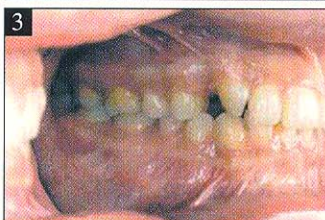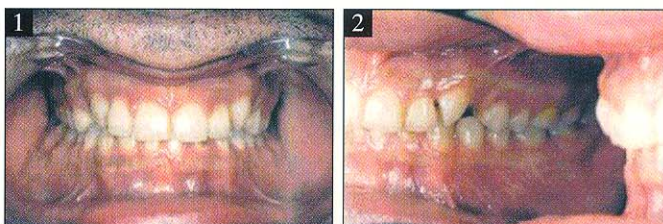
Continuous arch, with almost no bends and loops, does not bring about greater problems to the patient than labial appliance does.

Combined Orthodontic-Prosthetic treatment of malpositioned anterior teeth. (8)

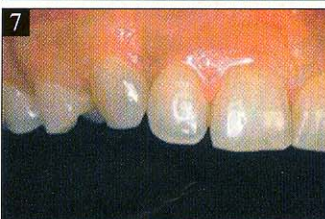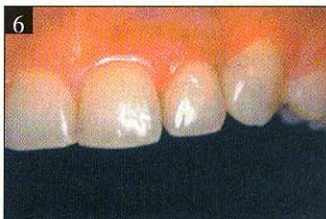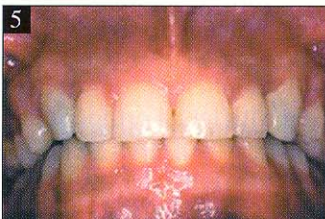A 26 years old male TV performer and singer had a skeletal and dental Class I malocclusion, with deep bite and increased overjet. He was complaining of an unaesthetic appearance due to rotated upper cuspids and to spaces that were left after the previous extraction of retained deciduous upper cuspids. A combined orthodontic-prosthetic solution was suggested. Treatment plan was to bring the

cuspids to their optimal position with no rotation and with minimal spaces between them and the lateral incisors and premolars. Porcelain laminates were then made up for the cuspids and first premolars in order to fill the proximal spaces.

Porcelain laminates were chosen because they would provide a stable and long lasting esthetic solution, while conserving tooth structure. The overall treatment time was 8 months, a comparatively short time. The patient's main problem was fully solved, and his appearance was maintained during all stages of the treatment.



1-3: At initial orthodontic examination: frontal and lateral views. Note the unaesthetic space between the cuspids and first premolar, and the rotated cuspids. : Provisional composite resin laminates.



5-7: At the end of treatment: single porcelain veneers, frontal and lateral views. Note the harmonic and esthetic occlusion.

Orthodontic-Prosthetic case presentation

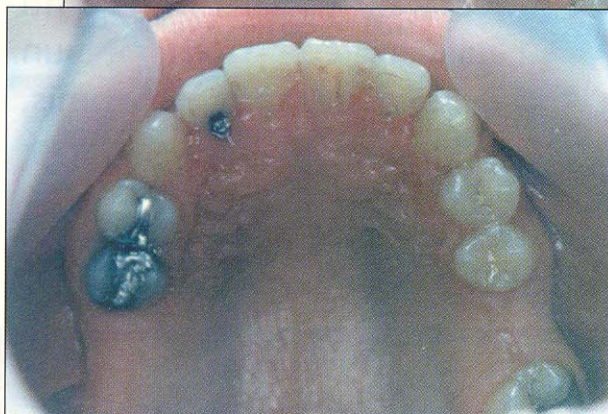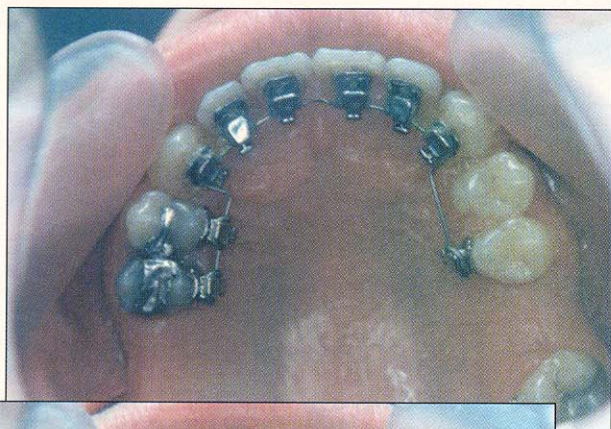
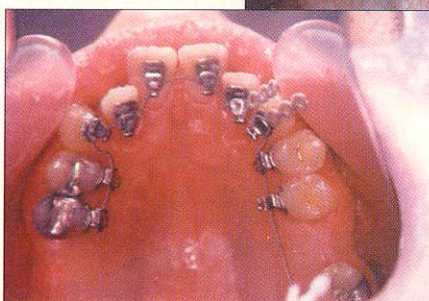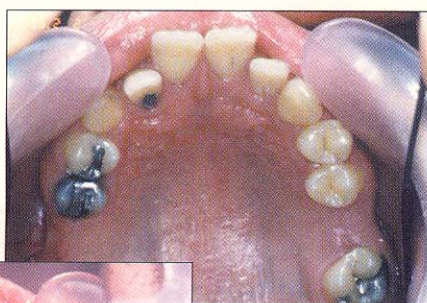B.T. a 26 years old man, was referred by his dentist for preparation to prosthetic and implant restoration. He presented a skeletal and dental class 3 malocclusion' with dished in profile, deep bite, anterior cross bite, scissor bite in the right segment between 14 and 45, over eruption of tooth 36 because of missing upper molars. The treatment plan included upper lingual and lower labial appliance, to level and align the occlusion. Ormco lingual brackets slot .018 were bonded in the upper arch and labial straight wire brackets, Roth prescription slot .022 were bonded in the lower arch. The first upper archwire was Respond .0175. A month later it was replaced with .016 Ni. Ti. preformed lin-

gual arch, with light intermaxillary elastics to correct the anterior cross bite.

The third upper arch was stainless steel .016, and it was placed 3 months from the beginning. Detailing of the occlusion was completed in 5 month. During this time teeth 11 and 12 were reshaped and restored with composite material. Total treatment time was 9 months. At the end of treatment two clear retainers were delivered to the patient. At this point he was referred back to his dentist for implant restoration.

Cephalometric results and superimposition shows posterior rotation of the mandible, improvement in upper and lower incisor position, improvement in nasolabial angle and E-line. Clinical evaluation reveals a good class 1 occlusion, overjet and overbite within normal limits, midlines are correct.

BEFORE, DURING AND AFTER TREATMENT



Disadvantages still to be overcome are: Further improvement of the design of the brackets to make them smaller, more easily ligated, and smoother to the tongue.

Reduction in speech distortion during the early stages of treatment, which can be distressing to the patient.

The addition of training in lingual orthodontics to the graduate or postgraduate orthodontic programs in the universities around the world.

Reduction of the high fees by improvements in design and technique which will, in ????????

References

1. Massimo Ronchin: Present Clinical Reality. Lingual Orthodontics, editor: R. Romano, B.C. Decker, 1998.
2. Mario E. Paz: Preserving the Hollywood Smile and Facial Profile. Lingual Orthodontics, editor: R. Romano, B.C. Decker, 1998.
3. Didier Fillion, The resurgence of Lingual Orthodontics, Clinical impressions 7(1), 1998
4. Christian Demange: Shape Memory wires in Lingual Orthodontics. Lingual Orthodontics, editor: R. Romano, B.C. Decker, 1998.
5. Dr. Didier Fillion: The thickness measurement system with the DALI program: an easy accurate lingual indirect bonding system. Lingual Orthodontics, editor: R. Romano, B.C. Decker, 1998.
6. Scot A. Huge: The CLASS System (Customized Lingual Appliance Set-Up Service). Lingual Orthodontics, editor: R. Romano, B.C. Decker, 1998.
7. Didier Fillion: Improving Patient comfort with Lingual Brackets, JCO 31(10): 689-694, 1997
8. Rafi Romano, Nitzan Bichacho: Combined Orthodontic-Prosthetic Treatment of Malpositioned Anterior Teeth. Lingual Orthodontics, editor: R. Romano, B.C. Decker, 1998.

voir *Le Monde Professionnel*, p. 79

Rafi ROMANO - C.V.

- 1984 D.M.D. (dental surgeon) in the Hebrew University Hadasah School of Dental Medicine.
- 1991 Post-graduated Orthodontic course in the Hebrew University Hadasah school of Dental Medicine.
- 1991 M.Se (Cum Laude) in the Hebrew University Hadasah school of Dental Medicine.
- 1991-1996 Member of the Orthodontic Department in the Hebrew University Hadasah school of Dental Medicine from
- 1994 Lingual Course: Dr. Didier Fillion, France
- 1994 Lingual Course: Dr. Mario Paz, USA
- 1993-1998 Editor: Journal of Israeli Orthodontic Society
- 1995-1996 Associate Member of: European Academy of Aesthetic Dentistry (EAED)
- 1997-1998 Active Member of: European Academy of Aesthetic Dentistry (EAED)
- 1998 Editor: Colour Atlas of Lingual Orthodontics (B.C. Decker publishing)
- 1998 Member of Ormco Elite Team in Europe.