

# Miniplates as skeletal anchorage for treating mandibular second molar impactions

Yasushi Inoue Miyahira,<sup>a</sup> Liliana Ávila Maltagliati,<sup>b</sup> Danilo Furquim Siqueira,<sup>b</sup> and Rafi Romano<sup>c</sup>  
*São Paulo, Brazil, and Tel Aviv, Israel*

Mandibular second molar impactions can be difficult to correct and might require surgery. A young man with an impacted mandibular right second molar was treated with a miniplate, which provided anchorage to upright the tooth. Although other devices are available, this technique appears to be predictable and quick, and has few side effects. (*Am J Orthod Dentofacial Orthop* 2008;134:145-8)

**T**he impaction of permanent teeth is a deviation of normal dental eruption patterns. Although the failure to erupt of mandibular second molars is not common, the incidence of impaction is between 0.6 per 1000 and 3 per 1000.<sup>1</sup> When it does occur, it usually becomes a great challenge to the orthodontist, because of the biomechanical difficulties and the frequent necessity for orthodontic treatment combined with surgery.<sup>2,3</sup> Various orthodontic therapeutic methods have been proposed, including fixed appliances with several shapes and sizes of loops and springs<sup>4-6</sup> and, most recently, skeletal anchorages such as implantable devices<sup>7-11</sup> in a surgical approach.<sup>12-14</sup>

In this article, we report a clinical case in which the mandibular right second molar impaction was treated by uprighting, achieved with a miniplate as skeletal anchorage, and discuss the advantages and disadvantages of this technique.

## DIAGNOSIS AND ETIOLOGY

The patient was first seen at 8 years of age, when he came for orthodontic screening. After anamnesis and clinical examination, initial records were taken. In the panoramic radiograph (Fig 1), we observed no pathologic events and a normal dental eruption sequence with the mandibular right second molar in its correct position. Because no signs of abnormal dental development or skeletal growth were found, the patient was asked to return every 6 months.

<sup>a</sup>Postgraduate student, Department of Orthodontics, School of Dentistry, Methodist University of São Paulo, São Paulo, Brazil.

<sup>b</sup>Professor, Department of Orthodontics, School of Dentistry, Methodist University of São Paulo, São Paulo, Brazil.

<sup>c</sup>Private practice, Tel Aviv, Israel.

Reprint requests to: Yasushi Inoue Miyahira, Department of Orthodontics, Methodist University of São Paulo, Rua do Sacramento, 230, São Bernardo do Campo, SP, 09640-000, Brazil; e-mail, [dr.yasushi@uol.com.br](mailto:dr.yasushi@uol.com.br).

Submitted, September 2006; revised and accepted, October 2006.

0889-5406/\$34.00

Copyright © 2008 by the American Association of Orthodontists.

doi:10.1016/j.ajodo.2006.10.026

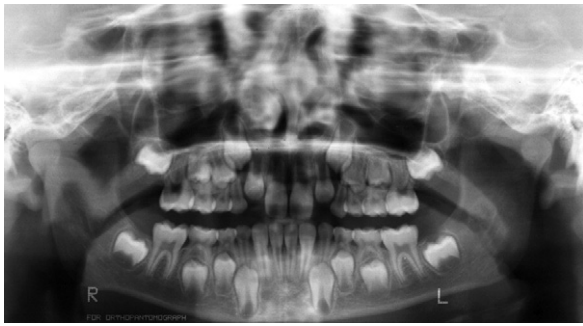
Unfortunately, he did not return until age 12, when his parents were concerned about the delayed eruption of the mandibular right second molar; the other second molars were already in the oral cavity. New records were taken to evaluate the status of the dentition, and the panoramic radiograph (Fig 2) showed that the mandibular right second molar had tipped mesially, approximately 45°, and was impacted between the distal root of the first molar and the crown of the third molar. The possible etiology was the premature development of the crown of the third molar, which had occupied the space for the second molar's eruption.<sup>15</sup> The treatment objectives proposed for this patient were to upright, level, and align the impacted tooth in relation to the other teeth in the mandibular arch, and obtain good occlusion and intercuspation.

## TREATMENT ALTERNATIVES

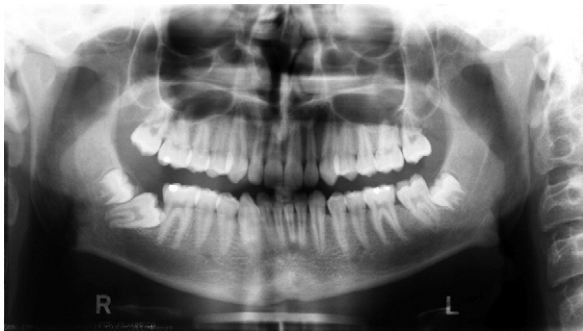One therapeutic method proposed for the treatment of impacted teeth is surgical repositioning. Although this procedure offers an immediate solution, it has some complications such as the necessity of further endodontic and periodontal treatments.<sup>12-14</sup>

Alignment with orthodontic appliances, supported by teeth only, has also been indicated for uprighting impacted mandibular molars, a method that has been extensively referred to in the literature, with various types of loops and springs used in fixed or removable appliances.<sup>2,3,16</sup> This great variety of loop and spring designs in the literature can partially explain the difficulty in resolving these situations, since the required force component is mainly in a distal direction, where there are no teeth in an adolescent patient.

The use of skeletal anchorage has a great advantage, since we can place the device distally to the impacted tooth and generate a counterclockwise moment that is favorable and provides the necessary uprighting and extrusion movement of this tooth.



**Fig 1.** Panoramic x-ray at age 8 years. Note the correct position of the dental bud of the mandibular right second molar.

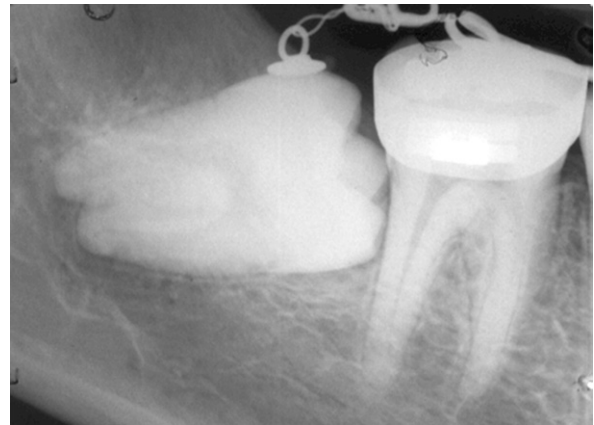


**Fig 2.** Panoramic x-ray at age 12 years. Note the severe mesial tipping of the mandibular right second molar, which is impacted between the distal root of the first molar and the crown of the third molar.

The miniplate was chosen over the more commonly used mini-implants because (1) the miniplate has a larger body that minimizes the chance of failure of bone integration; and (2) the point of force application is located in an upper area related to the center of resistance of the tooth and thus generates extrusion movement, as required, and not intrusion that usually is provided by miniscrews, which are normally positioned on cortical bone after or between the tooth roots.

#### TREATMENT PROGRESS AND RESULTS

To correct the inclination of the mandibular right second molar, the extraction of the third molar was indicated. On the occlusal surface of the second molar, an orthodontic accessory was bonded to enable application of force. Before using the miniplate, we attempted to tip this tooth back with a  $0.017 \times 0.025$ -in beta-titanium alloy wire cantilever. An edgewise appliance was bonded in the mandibular arch, reinforced by a lingual arch (0.9-mm stainless steel archwire) for anchorage. However, due to the limitation of this therapeutic procedure, some undesirable collateral ef-



**Fig 3.** Periapical x-ray several months after the start of orthodontic treatment. Note the undesirable increase of mesial tipping of the mandibular right second molar.

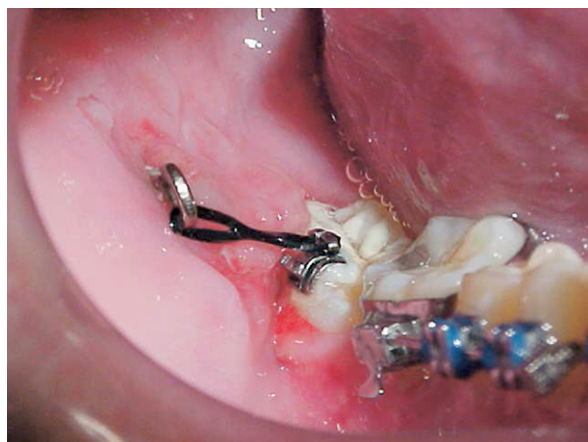fects were observed, and the mesial tipping of the tooth increased (Fig 3).

It was then decided to add skeletal anchorage. The device chosen was the miniplate, installed in the mandibular ramus to improve and facilitate mechanical uprighting of the tooth. The surgical procedure was performed in a dental office and comprised the fixation of a 4-hole T-shaped titanium plate with 2.0-mm diameter screws (Osteomed, Addison, Tex). The surgical approach consisted of an incision in the alveolar buccal mucosa, 2 cm distal to the mandibular right second molar, following the external oblique line of the mandible. After the mucoperiosteal flap was elevated, the plate was fixed by using 2 screws (10 and 12 mm in length), whereas the plate's largest part remained exposed in the oral cavity, practically parallel to the occlusal plane in a vestibular direction. A preparation was made in the end hole of the L plate to enable attachment of an elastic chain.

A bracket was bonded on the exposed coronal surface of the impacted tooth. The flap was sutured with 5-0 ethicom nylon (Johnson & Johnson, São Jose dos Campos, São Paulo, Brazil). The patient received medical treatment in the postoperative period with amoxicillin (500 mg), 1 capsule every 8 hours for 7 days, and anti-inflammatory medicine for 5 days. Mouth rinsing with chlorhexidine (0.12%) twice a day for a week was recommended.

Three months after attaching the miniplate and application of orthodontic force, the panoramic x-ray showed that the tooth was almost uprighted (Figs 4 and 5).

At this point, the miniplate was removed, and the tooth was included in the orthodontic appliance with edgewise mechanics, and, with an uprighting loop, the



**Fig 4.** Clinical picture of miniplate distal to the mandibular right second molar. The bracket on the impacted tooth was bonded onto the exposed surface, and the elastic chain was connected between the bracket and the miniplate.

tooth position could be improved and the treatment finished (Fig 6).

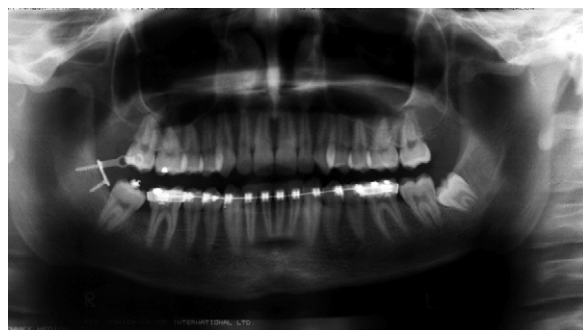After removal of the fixed appliance, the tooth was well aligned, and the roots were parallel to the neighboring molar (Fig 7). The correct position of the mandibular right second molar in relation to the first molar was obtained, as well as the correct occlusion with its antagonist. From the final result, we perceived that using miniplates as anchorage to upright impacted second molars is a simple orthodontic movement, making it faster and more efficient.

## DISCUSSION

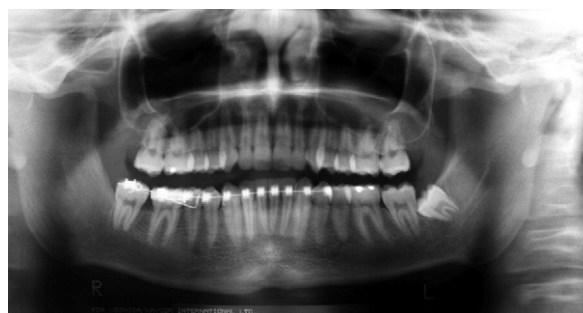This clinical case supports the report of Wellfelt and Varpio<sup>15</sup> that the more common impaction is unilateral on the right side rather than bilateral and most frequently in the mandible of male patients.

Whatever the treatment approach, it is important to deimpact the mandibular second molar as soon as it is diagnosed, because of the contact it establishes with the first molar; this could cause root resorption, caries, and periodontal problems on these teeth (Fig 8).

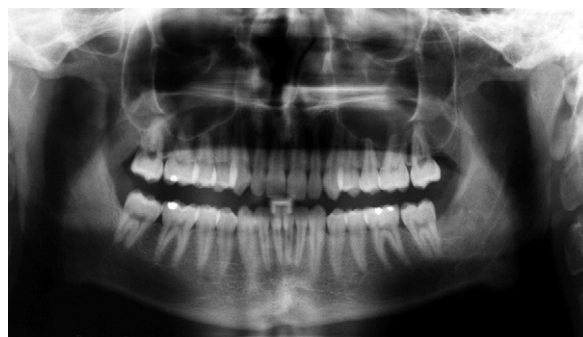Dental implants opened a new perspective in dentistry, but they require time for osseous integration, are difficult to remove, and usually have a high cost.<sup>11</sup> The introduction of miniscrews with immediate loading in orthodontics was a great improvement,<sup>10</sup> since they could be used for anchorage with the advantage of minimal collateral effects and enable the orthodontic movement to be more predictable.<sup>9,11</sup> They also allow applying a force from the distal side of an impacted molar; this is not possible with conventional ortho-



**Fig 5.** Panoramic x-ray 3 months after attaching the miniplate and application of orthodontic force. Uprighting and extrusion of tooth are nearly complete.



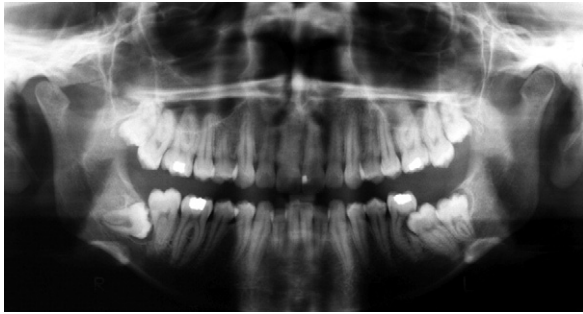
**Fig 6.** Panoramic x-ray after removal of the miniplate. The tooth is included in the orthodontic appliance.



**Fig 7.** Panoramic x-ray after removal of the fixed appliance. The tooth is well aligned, and the roots are parallel to the neighboring molar.

odontic devices. This force application generates a counterclockwise moment, allowing control of the movement and the collateral effects and, consequently, promoting rapid deimpaction and distalization of the crown.<sup>8,11</sup>

Although we have had good treatment results with the miniplate, it is not widely used, and, in most clinical cases reports, miniscrews of various commercial brands were used.<sup>7,8,10,11</sup>



**Fig 8.** Impacted mandibular second molars can lead to root resorption, caries, and periodontal problems.

Sherwood et al<sup>16</sup> reported that miniplates are a stable devices for anchorage. Choi et al<sup>17</sup> found that, in such areas, miniplates have high percentages of failure and mobility; they suggested that more studies should be performed for better evaluation. Miyawaki et al<sup>18</sup> showed that the inflamed tissues surrounding the mini-implant and the increased mandibular plane angle were associated with failure and motility of titanium screws of 10 mm or smaller.

In our patient, the orthodontic treatment was concluded successfully, with good clinical results. From this clinical experience, we believe that the use of miniplates is an accurate, safe, and simple method for skeletal anchorage, and it requires neither complex mechanotherapy as described by Majourau and Norton<sup>19</sup> nor the involvement of various teeth in the process.

Although miniplates are extremely useful, they have a few disadvantages in relation to conventional devices: the need for a surgical procedure, the relatively high cost, the difficulty of maintaining oral hygiene around the miniplate, and the risk of infection and discomfort in the first days because of the size of the device in the retro-molar region.

However, we consider it to be superior from the social and esthetic points of view, when compared with other conventional devices, such as Kloehn headgear, transpalatal bar, or Nance appliance.

We suggest that the general practitioner, pediatric dentist, or orthodontist should perform a radiographic follow-up of the dental eruption process to observe any delays in the eruption of the mandibular second molars. Early diagnosis can prevent impaction of these teeth, enabling a more conservative treatment approach.

## CONCLUSIONS

Skeletal anchorage, in cases of impaction of the mandibular second molars, enables the treatment plan

to be more predictable with minimal collateral effects. Among the devices for such treatment, miniplates are an efficient option.

We thank Carlos Veloso Salgado, bucco-maxillofacial surgeon, for the suggestion and accomplishment of the surgery.

## REFERENCES

1. Vedtofte B, Andreasen JO, Kjaer I. Arrested eruption of the permanent lower second molar. *Eur J Orthod* 1999;21:31-40.
2. Shapira Y, Borell G, Nahlieli O, Kufnec M, Stom D. Second molar impactions. *Angle Orthod* 1998;68:173-8.
3. Askosy AU, Aras S. Use of nickel titanium coil springs for partially impacted second molars. *J Clin Orthod* 1998;32:479-82.
4. Garcia-Calderon M, Torres-Lagares D, Gonzalez-Martin M, Gutierrez-Perez JL. Rescue surgery (surgical repositioning) of impacted lower second molars. *Med Oral Patol Oral Cir Bucal* 2005;10:448-53.
5. Gazit E, Lieberman M. A mesially impacted mandibular second molar. Treatment considerations and outcome: a case report. *Am J Orthod Dentofacial Orthop* 1993;103:374-6.
6. Kogod M, Kogod HS. Molar uprighting with the piggyback buccal sectional arch wire technique. *Am J Orthod Dentofacial Orthop* 1991;99:276-80.
7. Giacotti A, Muzzi F, Santini F, Arcuri C. Miniscrew treatment of ectopic mandibular molars. *J Clin Orthod* 2003;37:380-3.
8. Giacotti A, Arcuri C, Barlattani A. Treatment of ectopic mandibular second molar with titanium miniscrews. *Am J Orthod Dentofacial Orthop* 2004;126:113-7.
9. Melsen B. Overview mini-implants: where are we? *J Clin Orthod* 2005;39:539-47.
10. Kanomi R. Mini-implant for orthodontic anchorage. *J Clin Orthod* 1997;31:763-7.
11. Park HS, Kyung HM. A simple method of molar uprighting with micro-implant anchorage. *J Clin Orthod* 2002;36:592-6.
12. McAboy CP, Grumet JT, Siegel EB, Iacopino AM. Surgical uprighting and repositioning of severely impacted mandibular second molars. *J Am Dent Assoc* 2003;134:1459-62.
13. Johnson JV, Quirk GD. Surgical repositioning of impacted second molar teeth. *Am J Orthod Dentofacial Orthop* 1987;91:242-51.
14. Pogrel MA. The surgical uprighthing of mandibular second molars. *Am J Orthod Dentofacial Orthop* 1995;108:180-3.
15. Wellfelt B, Varpio M. Disturbed eruption of the permanent lower second molar: treatment and results. *J Dent Child* 1988;55:183-9.
16. Sherwood KH, Burch JG, Thompson WJ. Closing anterior open bites by intruding molars with titanium miniplate anchorage. *Am J Orthod Dentofacial Orthop* 2002;122:593-600.
17. Choi BH, Zhu SJ, Kim YH. A clinical evaluation of titanium miniplates as anchors for orthodontic treatment. *Am J Orthod Dentofacial Orthop* 2005;128:382-4.
18. Miyawaki S, Koyama I, Inoue M, Mishima K, Sugahara T, Takano-Yamamoto T. Factors associated with the stability of titanium screws placed in the posterior region for orthodontic anchorage. *Am J Orthod Dentofacial Orthop* 2003;124:373-8.
19. Majourau A, Norton LA. Uprighting impacted second molars with segmented springs. *Am J Orthod Dentofacial Orthop* 1995;107:235-8.